

Gossypiboma as a Rare Cause of Small Bowel Obstruction: A Case Report

Serghei Guțu¹, Iurie Țugui², Vasile Guzun², Ala Cerbadji², Eugen Guțu³, Gheorghe Rojnovceanu¹

¹Nicolae Testemițanu State University of Medicine and Pharmacy, N. Anestiadi Department of Surgery no. 1, Chișinău Republic of Moldova

²Municipal Clinical Hospital no.1, Department of Surgery, Chișinău, Republic of Moldova

³Nicolae Testemițanu State University of Medicine and Pharmacy, Department of General Surgery no. 3, Chișinău, Republic of Moldova

*Corresponding author:

Serghei Guțu, MD

Nicolae Testemițanu State University
of Medicine and Pharmacy

N. Anestiadi Department of Surgery
no. 1, Chișinău, Republic of Moldova

E-mail: gutsu-sergiu@mail.ru

Rezumat

Textilomul - cauză rară a ocluziei intestinale: prezentare de caz

Omiterea accidentală a corpurilor străini de natură textilă în cavitatea abdominală după laparotomie reprezintă o eroare medicală gravă, care are o incidență reală necunoscută și poate duce la complicații severe. Prezentăm cazul unei femei de 24 de ani la care meșa chirurgicală a migrat în lumenul jejunului și a provocat ocluzie intestinală. Înlăturarea corpului străin a necesitat laparotomie repetată și rezecție segmentară a ansei intestinale afectate. Lucrarea prezintă și analiza rezultatelor investigațiilor imagistice, precum și examinarea posibilelor motive care au dus la lăsarea neintenționată a corpului străin. Reducerea fiabilă a incidenței și a severității consecințelor după reținerea obiectelor chirurgicale textile în abdomen poate fi realizată numai prin îmbunătățirea standardelor de siguranță a pacientului, inclusiv numărarea minuțioasă a meșelor și utilizarea de rutină a materialelor cu markeri radiopaci.

Cuvinte cheie: textilom, migrație intraluminală, ocluzie intestinală, tomografie computerizată, factori de risc

Abstract

Unintentionally retained textile foreign bodies in the abdomen after laparotomy is a serious medical error, with unknown incidence which can lead to severe complications. We present the case of a 24-year-old woman with a retained surgical sponge

Received: 07.10.2020

Accepted: 10.12.2022

migrated into the jejunal lumen and causing an intestinal obstruction. Removal of the foreign body required repeated laparotomy and segmental resection of the affected intestinal loop. The article provides the analysis of the imaging diagnostic results, as well as possible reasons that led to the foreign body being left unintentionally. Reliable reduction of incidence and severity of consequences after retention of textile surgical objects in the abdomen can only be achieved through improved standards of patient safety, including careful sponge counting and the routine use of materials with radiopaque markers.

Key words: gossypiboma, intraluminal migration, intestinal obstruction, computed tomography, risk factors

Introduction

Unintentional leaving of gauze sponges in the abdomen after laparotomy is an infrequent but serious medical error. Depending on its location and evolution, the remaining foreign body can either undergo aseptic encapsulation, which leads to pseudotumor formation, or cause a local acute inflammatory response with abscess development (1,2). A much rare complication is spontaneous transmural migration of a surgical sponge into the intestinal lumen, resulting in mechanical intestinal obstruction (3). Diagnosis of foreign body as a cause of intestinal obstruction is often difficult due to the rarity of the condition usually unexpected by clinicians, possible long-term previous asymptomatic evolution, as well as nonspecific and poorly familiar to radiologists imaging findings (1,4).

Case Report

A 24-year-old woman was admitted urgently to our surgical department with intermittent diffuse abdominal pain, nausea and repeated vomiting. Physical examination revealed moderate abdominal distension and no tenderness or peritoneal irritation. Three months before, she underwent a left-sided colectomy for dolichocolon and chronic constipation syndrome in the same hospital. According to the operative report, the primary surgery was performed in the late afternoon. This in turn resulted in the change of the

scrub nurse. The surgical report also reflected the procedure of surgical sponges final counting. The postoperative period was uneventful, thus described symptoms appeared acutely, 2 days prior to the admission. Blood test showed marked anemia (hemoglobin: 86 g/L), normal leukocyte count ($5.9 \times 10^9/L$) and no neutrophilia (67%). The other biochemical parameters were within normal range. Plain abdominal x-ray revealed moderate distention of the ascending and transverse colon and suspicion of solitary small intestinal air-fluid levels (*Fig. 1*). Radiographic contrast studies found a delay in the advancement of barium along the small intestine, otherwise remaining inconclusive. However, abdominal computed tomography (CT) with intraluminal contrast revealed a marked distention of the proximal jejunal loops, as well as a blindly terminating loop of the small bowel within the right medium abdomen with a diameter of up to 5 cm, containing an obscure mass with the mixed liquid and air bubbles contents, surrounded by heterogeneous high-density walls (up to +200 Hounsfield units) (*Fig. 2*). The radiologist described the mass as an accumulation of barium over the site of incomplete intestinal obstruction. The patient underwent surgery with suspicion of adhesive intestinal obstruction, or strangulation of the small bowel loop inside internal hernia from mesosigmoid. During laparotomy, numerous dense adhesions were observed between the dilated jejunal loop and anterior abdominal wall at a distance of

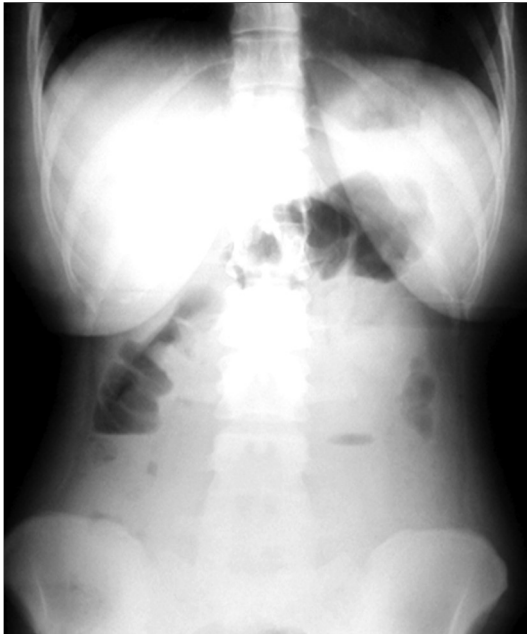


Figure 1. Plain abdominal radiograph on patient presentation showed only moderate distention of the ascending and transverse colon and solitary small intestinal air-fluid levels.

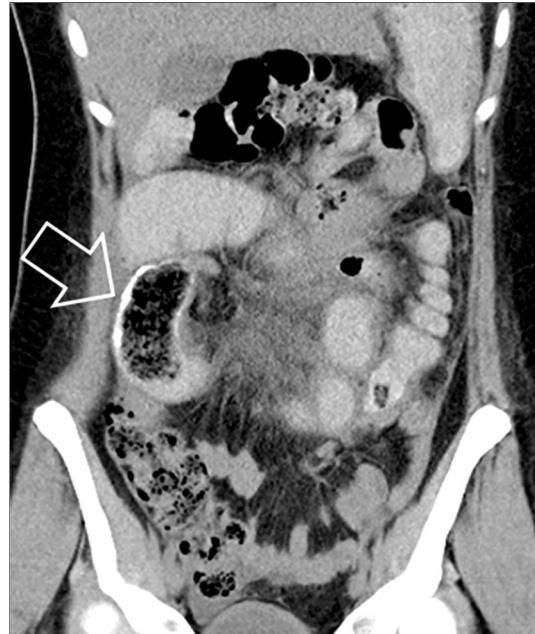

Figure 2. Abdominal CT with intraluminal contrast revealed a marked distention of the proximal jejunal loops, as well as a blindly terminating loop of the small bowel within the right medium abdomen with a diameter of up to 5 cm, containing an obscure mass with the mixed liquid and air bubbles contents, surrounded by heterogeneous high-density walls (arrow). Retrospectively, this finding represents an intraluminal migrated gauze sponge coated with barium.

about 100 cm from Treitz ligament. When separating the adhesions, the intestine was opened and a foreign body (a crumpled surgical sponge 9x4x4 cm) was removed from the lumen (*Fig. 3*). After partial resection of the damaged segment, intestinal continuity was restored by an end-to-end anastomosis. Postoperative histopathological examination of the resected bowel revealed the presence of macrophage granulomas with giant cells of “foreign body” type (*Fig. 4*). Anemia was compensated by the transfusion of 3 units of red blood cells. The patient had an uneventful recovery and was discharged 12 days after the intervention. After a year of follow-up, the patient had no symptoms.

Discussions

Retention of gauze sponges in the abdomen is an infrequent, preventable and serious medical error. Most reports on remained surgical items are insufficiently described in the medical literature. There are either reports on the single case or small series of cases (4,5). The real incidence of unintentionally left textile

objects after surgery is difficult to estimate, but it has been reported to be about 1 in 3000 intraabdominal procedures (6). However, it is

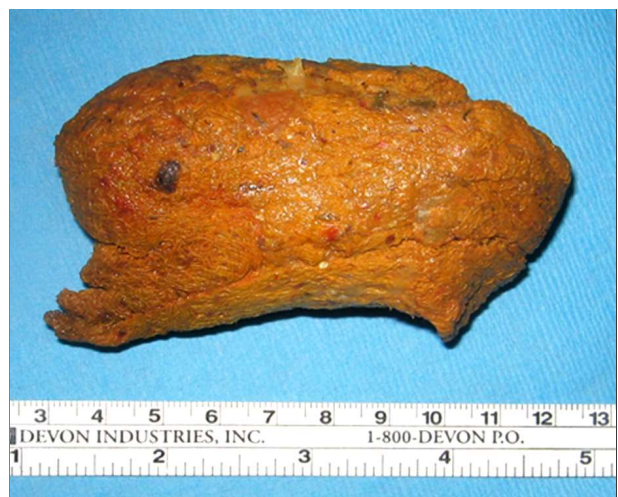

Figure 3. A crumpled retained surgical sponge 9x4x4 cm, spontaneously migrated into the lumen of the jejunum and caused mechanical intestinal obstruction

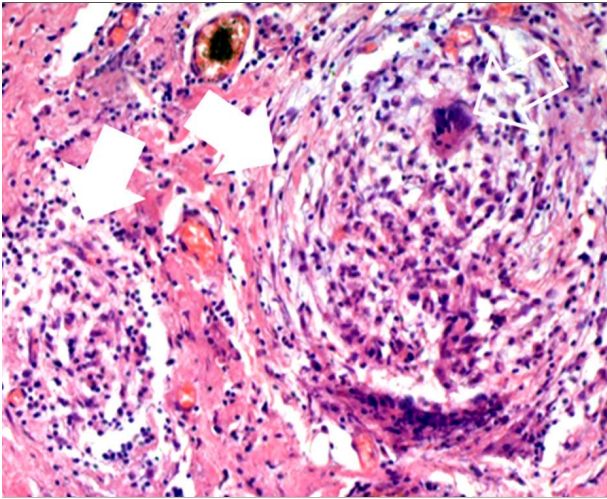


Figure 4. Postoperative histopathological examination of the resected bowel revealed the presence of macrophage granulomas (white arrow) with giant cells of "foreign body" type (empty arrow)

generally agreed that the incidence of gossypibomas is greatly underestimated, mainly due to the possible legal repercussions (7,8), but also because of a prolonged asymptomatic evolution in long run for many patients. The term "gossypiboma" is derived from the Latin word *gossypium* meaning cotton, and the word *boma* – place of concealment (1,7). Other terms that have also been used to describe this situation include *textiloma*, *cottonoid*, *cottonballoma*, *muslinoma* or *gauzeoma* (5,7,9). Probably, such a large number of terms are intended to limit the appearance in medical records of clearer and more understandable names of "textile foreign body".

According to medical literature patients with abdominal gossypiboma can have two main types of foreign body reactions to textile items: (1) an exudative infectious response leading to the formation of abscesses, fistulas, or intestinal obstruction; and (2) an aseptic fibrinous response that creates adhesions and encapsulations, granuloma or pseudotumor formation (1,2).

Erosion and penetration of a sponge into the gastrointestinal tract is an uncommon complication of gossypiboma. Foreign body pressure can result in fistulization of the adjacent hollow organ (3,5). The small intes-

tine is the most frequent site for intraluminal migration of sponge because of its thin wall and large outer surface (3,5). Foreign bodies can migrate completely into the small intestine without any visible opening in the intestinal wall (8). This process can take place over different times (weeks or years), but is ultimately detected due to its complications. Intestinal obstruction, which occurs as a result of spontaneous transmural migration of the sponge into the intestinal lumen, usually develops at the level of the ileocecal valve (2). In our observation, the surgical sponge left in the abdominal cavity was completely asymptomatic over 3 months. Only erosion of the bowel wall and partial occlusion of the proximal small intestine lumen by foreign body caused intestinal obstruction and the appearance of symptoms. It is likely that the initial anemia detected on the patient's admission could be explained by occult gastrointestinal bleeding from the edges of erosive intestinal defect.

By default, all standard diagnostic procedures such as radiography (if the sponge has a radiopaque marker), ultrasound, CT, and magnetic resonance imaging are capable to identify gossypiboma. Nevertheless, an abdominal CT is considered the method of choice, which typically demonstrates a "spongiform" mass with entrapped multiple small air bubbles and irregular thickening of the wall (2, 4). CT scan usually helps clinicians to suspect an intraluminal gossypiboma as well (7). In the presented case, the retrospective analysis of computed tomograms can reasonably state that a gauze sponge coated with barium was mistaken for accumulation of intestinal material mixed with contrast, due to its intraluminal location. Migration into the small intestine most probably led to additional accumulation of intraluminal gas by gossypiboma and altered its usual visual characteristics, thus imposing difficulties to determine the presence of an intraluminal surgical sponge. In addition, the left gauze sponge is a rather rare condition, which in turn determines the increased complexity of preoperative diagnostic, requires extra vigilance as well as special

experience of the results analysis (7). Radiologists often lack training experience in surgical sponge recognition and therefore possess incomplete information about what these objects might look like (10). Additional difficulty in foreign body recognition in the described case is caused by the routine use in Moldovan public hospitals of surgical sponges without X-ray positive marking. Although the use of radiographically detectable objects during laparotomy does not prevent their accidental retention in the abdominal cavity, it can significantly facilitate the differentiation of the sponge from other abnormal conditions when performing CT or even plain radiography (4,8).

Open surgery is the most reliable method of treatment for intra-abdominal foreign bodies (8,11). Removal of the foreign body was the only treatment in most of the previously reported cases of complete migration of the remaining surgical sponge into the intestine. However, in some cases (about 30%) the damaged intestine was also resected during laparotomy (7,11). In the reported case, the dense adhesions surrounding the probable site of intraluminal sponge migration made it impossible to preserve an intact intestine. This in turn required the resection of the damaged segment followed by intestinal anastomosis.

The medical literature has identified a number of risk factors associated with remained foreign bodies after laparotomy. Commonly these include: improper sponge counts, emergency procedures, uncontrolled bleeding, surgery after normal working hours, patient instability, unplanned change in surgical procedure, long duration of surgery, change of surgical team or operating nurse, patients with obesity (4,6,7,9). Apparently, the decisive factors of the presented clinical case were the late working hours of primary procedure, which was accompanied by the change of the scrub nurse, a fact also confirmed by the operative report. It is very likely that the change of surgical nurse subsequently led to incorrect count, or more precisely, falsely correct count of the surgical sponges.

Unfortunately, it has been established that most identified gossypibomas occur despite the “correct” counting done prior to completion of procedure (4,12). Different countries and different hospitals use their own systems for counting instruments and other items during surgery. However, universal standardization and adherence to operating room safety protocols should include preoperative and multiple postoperative sponge and instrument counts (6,13) in addition to careful postoperative exploration of the surgical site (13,14). Surprisingly, the surgical tools most often recounted during the surgery, i.e., sponges were most often missed (12). Therefore, for adequate preventive measures in the operating theatre, a revision of the patient safety standards is compulsory (9,10). The choice of strategy for each hospital depends on its resources, priorities and perceptions of the consequences of unintentional retention of textile foreign bodies in the abdominal cavity (14).

Conclusions

A surgical sponge left after laparotomy should be considered in the differential diagnosis of acute mechanical intestinal obstruction in any postoperative patient.

Computed tomography is the method of choice for diagnosis of abdominal gossypiboma. However, in case of intraluminal migration of a foreign body, CT may present atypical and inconclusive data.

As a rule, in order to remove the foreign bodies from the abdominal cavity, a second laparotomy is necessary. Induced resection of the affected bowel segment shall also be considered in the occurrence of the intraluminal migration with the development of intestinal obstruction.

The best approach to prevent gossypiboma can be achieved through strict adherence to current patient safety standards, multiple surgical material counting in addition to careful exploration of the surgical site at the end of the procedure. The routine use of surgical sponges with a radiopaque marker can be

easily identified radiographically in cases of doubt about the correctness of the count.

Conflict of Interest

The authors declare no conflicts of interests.

Ethical Statement

The study case was approved by the Ethics Committee of Nicolae Testemiãanu State University of Medicine and Pharmacy, no 48 of 12.02.2020.

References

1. Rajput A, Loud PA, Gibbs JF, Kraybill WG. Diagnostic challenges in patients with tumors: Case 1. Gossypiboma (foreign body) manifesting 30 years after laparotomy. *J Clin Oncol.* 2003;21(19):3700-1.
2. Tandon A, Bhargava SK, Gupta A, Bhatt S. Spontaneous transmural migration of retained surgical textile into both small and large bowel: a rare cause of intestinal obstruction. *Br J Radiol.* 2009;82(976):e72-5.
3. Zantvoord Y, van der Weiden RM, van Hooff MH. Transmural migration of retained surgical sponges: a systematic review. *Obstet Gynecol Surv.* 2008;63(7):465-71.
4. Gibbs VC, Coakley FD, Reines HD. Preventable errors in the operating room: Retained foreign bodies after surgery – Part I. *Curr Probl Surg.* 2007;44(5): 281-337.
5. Singhal PM, Vats M, Neogi S, Agarwal M. Asymptomatic gossypiboma with complete intramural migration and ileoileal fistula. *BMJ Case Rep.* 2019;12(6):e228587.
6. Gawande AA, Studdert DM, Orav EJ, Brennan TA, Zinner MJ. Risk factors for retained instruments and sponges after surgery. *N Engl J Med.* 2003; 348(3):229-35.
7. Obeidat KA, Aleshawi AJ, Alebbini MM, Bani Yasin SN. Abdominal intraluminal gossypiboma: Demographics, predictors of intraluminal site, diagnostic and treatment measures. *Clin Exp Gastroenterol.* 2020;13:65-72.
8. Sozutek A, Yormaz S, Kupeli H, Saban B. Transgastric migration of gossypiboma remedied with endoscopic removal: a case report. *BMC Res Notes.* 2013;6:413.
9. Wan W, Le T, Riskin L, Macario A. Improving safety in the operating room: a systematic literature review of retained surgical sponges. *Curr Opin Anaesthesiol.* 2009;22(2):207-14.
10. Chopra S, Suri V, Sikka P, Aggarwal N. A case series on gossypiboma – varied clinical presentations and their management. *J Clin Diagn Res.* 2015; 9:QR01-3.
11. Sozutek A, Colak T, Reyhan E, Turkmenoglu O, Akpınar E. Intra-abdominal gossypiboma revisited: Various clinical presentations and treatments of this potential complication. *Indian J Surg.* 2015;77(Suppl 3):1295-300.
12. Cima RR, Kollengode A, Garnatz J, Storsveen A, Weisbrod C, Deschamps C. Incidence and characteristics of potential and actual retained foreign object events in surgical patients. *J Am Coll Surg.* 2008;207(1):80-7.
13. Kaiser CW, Friedman S, Spurling KP, Slowick T, Kaiser HA. The retained surgical sponge. *Ann Surg.* 1996;224(1):79-84.
14. Regenbogen SE, Greenberg CC, Resch SC, Kollengode A, Cima RR, Zinner MJ, et al. Prevention of retained surgical sponges: a decision-analytic model predicting relative cost-effectiveness. *Surgery.* 2009;145(5): 527-35.