

## Surgical Attitude in Patients with Secondary Hyperparathyroidism Undergoing Dialysis

M.N. Bratucu<sup>1</sup>, N.D. Garofil<sup>1</sup>, P.A. Radu<sup>1</sup>, V. Paic<sup>1</sup>, M. Zurzu<sup>1</sup>, V. Goleanu<sup>4</sup>, F. Popa<sup>2</sup>, V. Strambu<sup>1</sup>, D.N. Straja<sup>3</sup>

<sup>1</sup>Department of General Surgery, "Carol Davila" Nephrology Clinical Hospital, Bucharest, Romania

<sup>2</sup>Department of General Surgery, "St. Pantelimon" Clinical Emergency Hospital, Bucharest, Romania

<sup>3</sup>Department of General Surgery, "Prof. Dr. Alexandru Trestioreanu" Oncological Institute, Bucharest, Romania

<sup>4</sup>Department of Cardiovascular Surgery, "Prof. Agripa Ionescu Hospital", Balotesti, Ilfov County, Romania

### Rezumat

#### *Atitudinea chirurgicală la pacienții cu hiperparatiroidism secundar supuși dializei*

**Introducere:** Hiperparatiroidismul secundar (SHPT) se dezvoltă, într-o măsură mai mică sau mai mare, la toți pacienții cu boală renală cronică. Patologia este cu atât mai severă cu cât survine la un bolnav deja tarat la care insuficiența renală cronică asociază frecvent comorbidități severe. Mortalitatea generală este mai mare decât în populația generală. Eșecul terapiei medicale reprezintă o indicație pentru paratiroidectomie.

**Metode:** Studiul a analizat un lot de 200 de pacienți cu SHPT și insuficiență renală cronică, admiși în clinică în perioada octombrie 2011 - ianuarie 2015. Au fost realizate 179 (89.5%) de paratiroidectomii totale și 14 (7%) subtotale. Totodată 7 (3.5%) intervenții au fost incomplete.

**Rezultate:** Mortalitatea generală a fost de 1% (2 pacienți) iar morbiditatea postoperatorie specifică 3.5% - 4 complicații hemoragice locale și 3 cazuri cu disfonie (12% dacă includem și reintervențiile chirurgicale pentru recurența hiperparatiroidismului - 17 pacienți).

**Concluzii:** Paratiroidectomia totală este grevată de un număr redus de complicații postoperatorii iar riscul recurenței hiperparatiroidismului este aproape inexistent. Dezavantajele acestei intervenții sunt reprezentate de tendința la hipocalcemie postoperatorie imediată și de substituția pe termen lung cu calciu și vitamina D.

**Cuvinte cheie:** hiperparatiroidism secundar, paratiroidectomie totală, paratiroidectomie subtotală, SHPT

### Abstract

**Background:** Secondary hyperparathyroidism (SHPT), develops, more or less in all the patients with chronic kidney disease. The pathology is even more severe as it intervenes in a suffering patient in whom the chronic kidney disease frequently associates severe comorbidities. General mortality is higher than in general population. The failure of the medical therapy is an indication for parathyroidectomy.

**Methods:** The study analyzed 200 patients with SHPT and chronic kidney disease, admitted in the clinic from October 2011 until January 2015. In this period, 179 (89.5 %) total parathyroidectomies have been performed along with 14 (7%) subtotal parathyroidectomies. Also 7 (3.5%) surgical interventions were incomplete.

**Results:** Overall mortality was 1% (2 patients) and postoperative specific morbidity 3.5% - 4 local hemorrhagic complications and 3 cases of dysphonia have been encountered (12% if we

### Corresponding author:

Victor Dan Eugen Strambu, MD  
Department of General Surgery  
"Carol Davila" Nephrology Clinical Hospital  
Grivitei street, no. 4, sector 1, Bucharest  
Romania  
e-mail: drstrambu@gmail.com  
bratucu\_mircea@yahoo.com

include the reinterventions for recurrent hyperparathyroidism - 17 patients).

**Conclusions:** Total parathyroidectomy is encumbered by a reduced number of postoperative complications and the risk of recurrent disease in almost nonexistent. The disadvantages of this surgical approach are the tendency of immediate postoperative hypocalcemia and long term substitution with calcium and vitamin D.

**Key words:** secondary hyperparathyroidism, total parathyroidectomy, subtotal parathyroidectomy, SHPT

## Introduction

Secondary hyperparathyroidism (SHPT) develops, on a larger or smaller scale, in all patients with chronic kidney disease (CKD). The pathology becomes even more severe as it is found in an already ailing patient where the chronic renal disease is frequently associated with severe arterial hypertension, chronic ischemic heart disease, coagulatory disorders, chronic hepatitis type B or C, hyperkalemia. The hyperplasia of the parathyroid glands, secondary to the chronic renal failure, adds to the effects mentioned above bone, vascular, cardiac and nervous manifestations. General mortality is 6.4 to 7.8 times greater for these patients than the general population (1,2).

The incidence of chronic kidney disease in 2008 is between 1.9 and 2.3 million in Canada (3) and was estimated that in 2007, the disease was affecting approximately 8.8% of the population of Great Britain (4). According to the National Health Insurance Agency, in 2014, in Romania, the number of patients treated through dialysis was 11392.

Parathyroidectomy is the curative treatment of SHPT. Regarding the surgical technique for SHPT there is no singular mindset, multiple options being available, each of which is subjected to controversies regarding its benefits and drawbacks. Total parathyroidectomy, subtotal parathyroidectomy or total parathyroidectomy with autotransplant represent the current surgical options in the treatment of SHPT.

The interest for this pathology stands in the severity of the disease, the small number of medical centers where this glandular surgery is performed and the rich casuistry present in our surgery clinic.

This study seeks to offer a realistic solution regarding the management of patients suffering from prolonged renal failure with additional endocrine pathology.

## Material and Method

A retrospective study was made on a group of 200 patients with secondary hyperparathyroidism (SHPT) added to chronic renal failure, having been hospitalized between October 2011 and January 2015. All the patients have undergone surgical intervention. All the patients were part

of the renal dialysis program, 187 hemodialysis (93.5%) and 13 cases of peritoneal dialysis (6.5%).

During hospital admission, the research purposes were explained to potential subjects and the informed consent was obtained.

Demographic, clinical, biochemical, imagistic, surgical, and histological details were recorded in a database. Demographic data included age, gender, occupation, primary disease that resulted in CKD, dialysis modality (hemodialysis or peritoneal dialysis) and frequency, total months or years of dialysis, presence of comorbidities. Blood cell counts, blood biochemistry, serum calcium, inorganic phosphate and PTH were measured preoperatively; at 5-7 days postoperatively were measured again and at follow-up visits. They received follow-up at 6 months postoperatively. PTH values were also measured immediately after surgical intervention (second generation assay kit ("intact PTH") : LIAISON N-tact PTH).

## Results

The gender distribution was approximately equal and included 104 women and 96 men. The greatest incidence of the disease was recorder for patients ranging between 40 and 60 years of age with a total of 119 cases, representing 59.5% of all cases.

Most patients developed SHPT after a minimum of 3 years after the start of the dialysis treatment, with a maximum incidence rate between 6 and 10 years (121 patients). Incidence drastically declined after 11 years from the start of the dialysis treatment (20 patients).

The clinical table was dominated by muscle and osteo-articular pain, present in 100% of cases; fatigue was also present in all patients in the clinical study. 30% of patients (60 cases in total) developed itching in varying degrees of intensity. Further disorders included mood swings, depression and irascibility. (17% - 34 patients).

Comorbidities in the clinical study patients included arterial hypertension (173 cases - 86.5%), chronic ischemic heart disease (52 cases - 25%), chronic viral hepatitis in 47 cases (23.5%) of which 26 cases representing hepatitis C (13%), 17 cases of hepatitis B (8.5%) and 4 cases with both viruses present (2%). At 26 patients (13%) associated thyroid pathology was present. 8 patients (4%) presented diabetes and 4 patients (2%) had undergone kidney transplant.

Mean preoperational values of the parathormone (PTH) were 1405 pg/ml (normal values 17.3 - 73 pg/ml); most patients (141 cases - 70.5%) presented preoperative values of over 1000 pg/ml of the PTH.

186 patients (93% of cases) benefited from an ultrasonography of the cervical region. Parathyroid scintigraphy was performed in 62 cases (31% of cases), CT of cervical region in 7 cases (3.5%) and MRI in 4 cases (2% of cases).

Surgical intervention was recommended after the failure of the medical treatment (repeated PTH values of over 600 pg/ml, associated with hypercalcemia, hyperphosphatemia or osteoporosis, or the persistence of symptoms).

Of the 200 surgical interventions, 179 (89.5%) were total

parathyroidectomies and 14 (7%) were subtotal parathyroidectomies. The subtotal interventions were used for young patients, candidates for kidney transplant. In 26 of cases (13%), simultaneous surgical interventions were performed on the thyroid gland (lobectomies or total thyroidectomies). The challenge presented was the intraoperative identification of a minimum 4 parathyroid glands (we also routinely explored the thyrothymic ligament and cranial portion of the thymic horns); once the glands had been highlighted, the decision would be made to whether the surgical intervention would be total or subtotal (depending on the age of the patient and the possibility of a kidney transplant). Impossibility to isolate at least 4 parathyroid glands was considered an incomplete surgical intervention. 7 of the cases (3.5%) were registered as incomplete, only 3 parathyroid glands having been highlighted; in all of these cases, the fourth gland was proven to have been ectopic – 5 anterior mediastinal locations (2.5%) and 2 intrathyroidal locations (1% of cases).

General anesthesia with orotracheal intubation was used, with the placement of a second small intubation tube at the level of the esophagus, in order to be used as an intraoperative landmark. The thyroid lodge was approached through a Kocher cervicotomy in all of the cases, with thorough bilateral exploration of the cervical region and of the thymic horns (Fig. 1). Impossibility to identify the 4 parathyroid glands also imposed the exploration of the sites of ectopic locations (retro-esophageal, juxta-cricoid, carotid sheath and lower thymic). In all cases, aspiration drainage of the thyroid lodge was used at the end of the intervention.

The histopathological examination revealed either diffused parathyroidal hyperplasia (134 cases – 67%), nodular hyperplasia (20 cases – 10%) or mixed hyperplasia (46 cases – 23%).

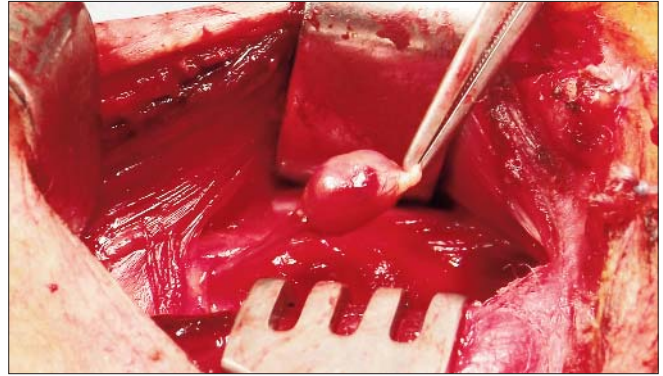
In most cases, directly after surgery, the decrease of the parathormone values was observed. There was a marked decrease noted in the 179 cases of total parathyroidectomy (average PTH immediately after intervention 23.52 pg/ml) and less marked in the 14 cases of subtotal parathyroidectomy (average PTH 58.7 pg/ml). In the 7 cases of incomplete intervention, the average postoperative PTH value was 387.1 pg/ml.

The serum calcium at immediately postoperative level had a tendency of decreasing and needed medical correction.

Complications that arose were acute myocardial infarction, 2 cases (1%), one of which presented ventricular fibrillation, successfully resuscitated, with favorable evolution with treatment, the second one developing towards exitus. Also, one of the patients presented a postoperative stroke, also having an unfortunate development towards decease.

For all patients undergoing total parathyroidectomy (179 cases) postoperative calcium was administered in order to prevent hypocalcemia.

In 4 cases (2%), local hemorrhagic complications occurred. Of these, in 3 cases the bleeding was quantitatively moderate (50-70 ml in a few hours) and required surgical reintervention; it has been confirmed that the bleeding was only superficial. In situ hemostasis was performed (along side hemostatic sponges), later development being favorable. One patient (0.5%) presented an important postoperative bleeding with



**Figure 1.** Right inferior parathyroid gland dissected along with its vascular pedicle

hemorrhagic shock, emergency surgical reintervention being required. For this patient, during surgical reintervention, the slipping of the ligature located at a branch of the inferior thyroidal pedicle level was observed. The ligature was reset into place and hemostatic sponges were applied. The postoperative evolution was favorable.

Transient dysphonia, second to the lesion of the recurrent laryngeal nerve, was encountered in 3 cases (1.5%).

Surgical reinterventions for the recurrence of the hyperparathyroidism were necessary in 17 cases (8.5%) and were based on either undetectable ectopic localizations during the first surgical intervention (7 cases – 3.5%) or cases in which, at the first intervention, subtotal parathyroidectomy was performed. Supernumerary parathyroid glands were not encountered.

The average hospitalization period was 8.5 days (3 to 19 days), with the percentage of total parathyroidectomies being 89.5% (179 patients). The patients were discharged after normalization of calcaemia, later benefiting from follow-up consultations at 6 months after the surgical intervention, during which intervals monitoring was performed by nephrology specialists (including PTH levels).

General mortality from the group of 200 patients was 1% (2 cases) and postoperative morbidity was 3.5% (4 local hemorrhagic complications and 3 cases of hoarseness). If we are to include reinterventions for the recurrence of hyperparathyroidism (17 cases in total) we can observe a postoperative morbidity of 12% (24 patients).

## Discussions

Surgical intervention for hyperparathyroidism secondary to chronic kidney failure is currently recommended in cases where the medical treatment fails to improve the patients symptomatology or when adverse effects of the medication appear, when parathormone presents values over 600 pg/ml associated either with hypercalcemia (or hypophosphatemia), or osteoporosis or calciphylaxys (5).

The symptomatology of the patients under medical treatment can become severe. Thus, muscle and osteoarticular pains, treatment resistant itching and extraskeletal and vascular

calcification, progressive under treatment, represent a good indication for surgical excision of the parathyroid glands. That being said, the surgical indication remains debatable (6). Regarding PTH values, indicating parathyroidectomy, there are different levels on a global scale. Thus, in Japan, parathyroidectomy is recommended for PTH values of over 500 pg/ml (6,7). The International Nephrology Society's Guide currently considers surgical intervention as being advisable if PTH levels pass 600 pg/ml (7, 8, 9). On the other hand, other authors take parathyroidectomy into consideration starting at PTH values exceeding 800 pg/ml (5). We have opted for parathyroidectomy for PTH values exceeding 600 pg/ml. Existing studies reveal an increase in mortality when parathormone values exceed 600 pg/ml (10, 11).

The majority of patients presented themselves late in the clinic, with severe symptomatology and greatly increased values of PTH (average value being 1405 pg/ml).

Regarding the preoperative imaging for these patients, we consider that an ultrasound of the cervical region should be conducted regularly for all patients, regardless of its obvious limitations. Having a sensitivity of 34-60% in detecting parathyroid adenomas (12, 13) with sizes of over 0.8 cm and a specificity of 90-95% (13), ultrasound is highly dependent on the experience of the examiner. Regarding the identification of ectopic glands, its value is limited (12). The other imaging methods are also not infallible in detecting glandular hyperplasia in SHPT (the goal is to visualize all of the glands), the sensitivity of parathyroid scintigraphy being at 50-60% (13, 14), that of the MRI at 50- 75% (13, 15) and that of the CT with intravenous contrasting agent at 40% (13).

Parathyroidian scintigraphy with Tc99m-sestamibi, CT or MRI were not conducted routinely. The conclusions of several authors was that up to 30% of cases of these imagistic investigations were unable to highlight supernumerary or ectopic glands preoperatory (5, 16), the results also being unsatisfying in highlighting all the hyperplastic parathyroid glands (17). In all cases of post operatory recurrence of secondary hyperparathyroidism (17 cases) we performed parathyroidian scintigraphy, highlighting the presence of a single parathyroid gland. In cases of recurring SHPT, we consider a combined evaluation useful, using ultrasound and parathyroid scintigraphy or CT/MRI or CT with positron emissions (PET-CT) (18). In the case of a SHPT recurrence, this combined imagistic evaluation leads to a greater surgical success of over 90% (12).

There currently exists a consensus regarding the medical treatment of SHPT – the desired effect is the medical control of the disease through lowering the amount of phosphates in the diet, administration of phosphate chelators, calcium supplements and vitamine D as well as calcimimetic agents.

Things are not so with the surgical method chosen, every one of the methods having its own supporters (5). Subtotal parathyroidectomy, total parathyroidectomy or total parathyroidectomy with autotransplant represent a great debate issue and there are many controversies surrounding the benefits and drawbacks of each procedure.

Regardless of the surgical method chosen, the success of

the surgical intervention leads to the lowering of parathormone values and the improvement of the symptomatology (6, 19). Through these surgical methods, the desired effect is the reduction of morbidity and mortality and an improvement in the general life quality of the patients (20).

*Total parathyroidectomy*, unlike the other surgical methods, presents with a nearly inexistent risk of postoperative relapse (0-4%) (5, 6, 21, 22). The drawbacks of the method are represented by the chance of postoperative tetany crisis and appearance of osteopenia in the patients as well as the long term replacement of calcium and vitamin D. We preferred this type of intervention for our patients (in 89.5% of cases) due to the extremely low rate of SHPT recurrence. In the case of a recurrence, the patient would undergo a new surgical intervention that brings along with it all the possible complications, adding a plus to morbidity and mortality rates.

*Total parathyroidectomy with immediate autotransplant* at forearm or cervical (in the sternocleidomastoid muscle) levels represents another surgical option for patients with SHPT. The benefit of this technique stands in the preservation of the parathyroid tissue capable of secreting parathormone; at the same time, surgical reintervention in the case of recurrence due to the hyperplasia of the autotransplanted glandular tissue is made much easier, in this case morbidity rates also being low (the autograft is superficially placed at forearm level, easily surgically accessible, with only local anesthesia). The drawbacks are represented in the possibility of diffuse seeding with parathyroid tissue of the forearm or the cervical region, prolonged postoperative periods of hypocalcemia or the possibility of autotransplanting neoplastic tissue. The autoimplanted tissue requires 2-3 weeks before it becomes functional (23). The recurrence rates for SHPT are greater than those found in total parathyroidectomy without autotransplant, the bibliography citing percentages of 8% (25), 16% (26), 20% (24) and even 76% (24).

*Subtotal parathyroidectomy* represents the third surgical option for patients suffering from SHPT and implies the removal of 3 glands and another half (or three quarters) of the fourth, preserving 40-70 mg of tissue from the fourth gland (usually the inferior gland with regular appearance). The short postoperative hypocalcemia represents an advantage for this method. The drawbacks of the method are represented by the possibility of seeding of the cervical region with parathyroid cells, and, in several cases, the impossibility of picking the remaining tissue from the gland that has the most regular appearance. Last but not least, the recurrence risk for the disease is greater than that seen in the total parathyroidectomy, reaching values up to 20% (6). In the case of surgical reintervention for SHPT, exploration of the cervical region becomes more difficult and exposes the patient to the risk of recurrent laryngeal nerve damage (6); general anesthesia is necessary. The recurrence rates of SHPT are similar to that of total parathyroidectomy with autotransplant (17).

An alternative to the subtotal parathyroidectomy method described above was accomplished by B. Stanescu (27). This technique implies placing the remaining inferior parathyroid tissue, with his vascular pedicle, cranially from the suprasternal

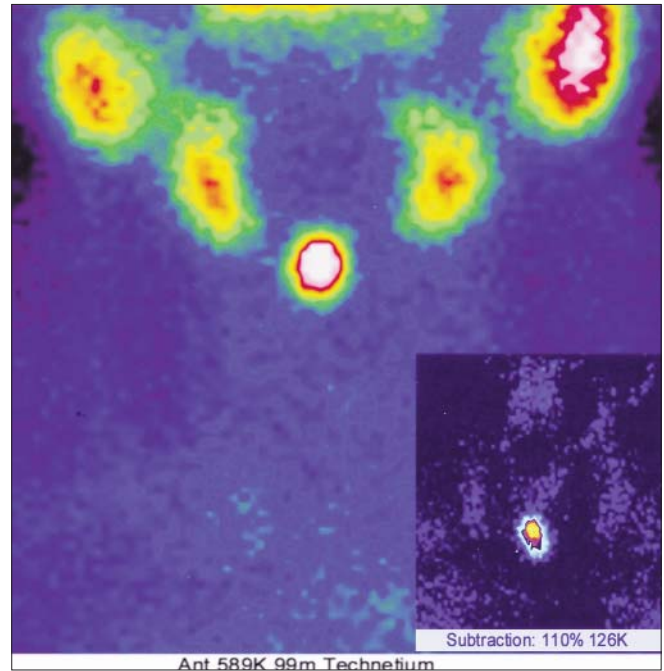
notch in the subcutaneous tissue. In order to do this, the inferior gland is dissected and moved above the suprasternal notch, is fixed in place with 1-2 wires at the subhioidian muscle and then the gland is subtotally sectioned. The adenomatous appearance of both inferior parathyroids or a short vascular pedicle represent contraindications for this procedure. There are some advantages of this method to the classic technique. Having maintained vascularization, the glandular preserved remnant is functional starting with the end of the intervention. The remaining glandular fragment is thusly no longer located in the thyroid lodge, being, in the case of a surgical reintervention, much more accessible (Fig. 2). The risk of damage to the laryngeal nerve is eliminated. Reintervention can be done with local anesthesia (risks of general anesthesia are eliminated) and preoperative scintigraphy testing is not necessarily required.

Of the 200 surgical interventions for SHPT, 179 (89.5%) were total parathyroidectomies and 14 subtotal parathyroidectomies (7%) and 7 (3.5%) were considered incomplete (during the operation, only 3 parathyroid glands could be identified). Of the 14 subtotal interventions, 2 were accomplished by the suprasternal subcutaneous placement of the glandular remnant (B. Stanescu).

In the cases that benefited from radical excision of the parathyroid glands, severe postoperative hypocalcemia was aggressively treated with intravenous calcium administration, leading to a longer hospitalization period as opposed to the patients treated with subtotal parathyroidectomy. The average hospitalization period was 8.5 days (between 3 and 19 days), for a percentage of total parathyroidectomies of 89.5% (179 patients). The bibliography cites average hospitalization periods of 5 to 6 days (28), going as high as 10.5 days (23), for patients who had predominantly undergone subtotal parathyroidectomies or total parathyroidectomies with autoimplant.

Recurrence of the disease was present in 17 patients. All the patients underwent cervical ultrasound and scintigraphic examination, later undergoing surgical reintervention. The criteria the surgical reinterventions were based on were the same as for the first intervention. Of the 14 subtotal parathyroidectomies, 10 cases (71.4%) required surgical reintervention for the recurrence of SHPT. Of the 7 cases (3.5%) where the intervention was considered incomplete (only 3 parathyroid glands could be identified during the surgery) all presented the recurrence of the disease. For these 7 cases, the 4th gland was later proven to be ectopic, with anterior mediastinal localization for 5 patients (2.5%) and 2 intrathyroid localizations (1%). Although supernumerary glands are described in the bibliography with an incidence rate of 0.6% to 14% (29), these were not encountered in our group.

Leaving postoperative hypocalcemia aside, the rate of complications in total parathyroidectomy is very low, being emphasized in our own group where we identified 4 cases of local bleeding and 3 cases with general complications – acute myocardial infarction and stroke. Also, both the general mortality as well as specific postoperative morbidity were low – 1% (2 cases) of mortality and 3.5% (7 cases) of morbidity. Morbidity reaches a percentage of 12% (24 patients) if we



**Figure 2.** Scintigraphy examination: a patient who underwent subtotal parathyroidectomy with suprasternal subcutaneous placement of the remaining inferior parathyroid and subsequently developed recurrence of the disease

include the 17 patients who had to undergo surgical reintervention for the relapse of SHPT.

According to international bibliography, parathyroidectomy is able to improve osteoarticular pains, muscle asthenia, itching, fatigue, depressive anxiety syndromes, calciphylaxia and lower the risk of fracture (19, 22, 30, 31, 32). Postoperative we can see improvement of anemia, hypertension, nutritional status and immunologic functions (33, 34, 35).

Cardiac valvular and vascular calcification, once present, are irreversible (6, 26, 30).

Parathyroidectomy is able to improve survival of these patients (6, 20). Also in our patients the remission of symptomatology was encountered after surgery.

## Conclusions

The majority of patients with SHPT present themselves late to the surgical service, with severe symptomatology and with parathormone levels of over 1000 pg/ml (70.5% of cases). The medical treatment must not be extended more than necessary when it no longer shows the desired results.

Surgical intervention can reduce PTH levels and significantly improve symptomatology.

Total parathyroidectomy presents itself with low SHPT relapse rates, the surgical intervention being encumbered by a low number of postoperative complications. The risk of relapse of the disease is nearly inexistent, and the disadvantages of the method being represented by immediate postoperative hypocalcemia, perfectly treatable, but increasing hospitalization

periods, and long term substitution of calcium and vitamin D.

For young patients, who are candidates for kidney transplants, at which subtotal parathyroidectomy is recommended, the suprasternal subcutaneous placement of the inferior parathyroid restant tissue along with the pedicle, represents an alternative to the classic method.

Parathyroid surgery should be performed in specialized centers.

### Acknowledgement

This paper is supported by the Sectorial Operational Programme Human Resources Development (SOP HRD), financed from the European Social Fund and by the Romanian Government under the contract number POSDRU/159/1.5/S/132395

### References

1. Trainor D, Borthwick E, Ferguson A. Perioperative management of the hemodialysis patient. *Semin Dial.* 2011; 24(3):314-26.
2. Corneci M, Stanescu B, Trifanescu R, Neacsu E, Corneci D, Poiana C, et al. Perioperative management difficulties in parathyroidectomy for primary versus secondary and tertiary hyperparathyroidism. *Maedica (Buchar).* 2012 ;7(2):117-24
3. Levin A, Hemmelgarn B, Culeton B, Tobe S, McFarlane P, Ruzicka M, et al. Guidelines for the management of chronic kidney disease. *CMAJ.* 2008 Nov 18; 179(11): 1154–1162.
4. Morgan T . Chronic Kidney Disease (stages 3–5) prevalence estimates using data from the Neoerica study (2007). Association of Public Health Observatories (Internet). 2009 Jan. Available from: <http://www.apho.org.uk/resource/item.aspx?RID=63798>
5. Madorin C, Owen RP, Fraser WD, Pellitteri PK, Radbill B, Rinaldo A, et al. The surgical management of renal hyperparathyroidism. *Eur Arch Otorhinolaryngol.* 2012; 269(6): 1565-76.
6. Tominaga Y, Matsuoka S, Uno N. Surgical and Medical Treatment of Secondary Hyperparathyroidism in Patients on Continuous Dialysis. *World J Surg* (2009) 33:2335–2342
7. Fukagawa M, Yokoyama K, Koiwa F, Taniguchi M, Shoji T, James Kazama J., et al. Clinical Practice Guideline for the Management of Chronic Kidney Disease-Mineral and Bone Disorder. *TherApher Dial.* 2013 ;17(3):247-88
8. Kidney Disease: Improving Global Outcomes (KDIGO) CKD-MBD Work Group. KDIGO clinical practice guideline for the diagnosis, evaluation, prevention, and treatment of Chronic Kidney Disease-Mineral and Bone Disorder (CKD-MBD). *Kidney Int Suppl.* 2009 ;(113):S1-130.
9. Uhlig K, Berns JS, Kestenbaum B, Kumar R, Leonard MB, Martin KJ, et al. KDOQI US commentary on the 2009 KDIGO Clinical Practice Guideline for the Diagnosis, Evaluation, and Treatment of CKD-Mineral and Bone Disorder (CKD-MBD). *Am J Kidney Dis.* 2010 May;55(5):773-99.
10. Block GA, Klassen PS, Lazarus JM et al. Mineral metabolism, mortality, and morbidity in maintenance hemodialysis. *J Am Soc Nephrol* 2004;15:2208–18.
11. Kalantar-Zadeh K, Kuwae N, Regidor DL et al. Survival predictability of time-varying indicators of bone disease in maintenance hemodialysis patients. *Kidney Int* 2006;70:771–80.
12. Cheng D, Jacob LA, Scoult L. Parathyroid Imaging. In :Oertli D, Udelsman R, editors. *Surgery of the Thyroid and Parathyroid Glands.* Heidelberg: Springer; 2007. p. 245-260
13. Sturgeon C, Caron N, Duh QY. Reoperative Parathyroid Surgery. In: Oertli D, Udelsman R, editors. *Surgery of the Thyroid and Parathyroid Glands.* Heidelberg: Springer; 2007. p. 339-348
14. Goris ML, Basso LV, Keeling C. Parathyroid imaging. *J Nucl Med.* 1991; 32:887–889
15. Gotway MB, Reddy GP, Webb WR, Morita ET, Clark OH, Higgins CB. Comparison between MR imaging and <sup>99m</sup>Tc MIBI scintigraphy in the evaluation of recurrent of persistent hyperparathyroidism. *Radiology.* 2001; 218:783–790
16. Milas M, Weber CJ. Near-total parathyroidectomy is beneficial for patients with secondary and tertiary hyperparathyroidism. *Surgery.* 2004; 136:1252-1260
17. Gasparri, G, Camandona, M, Abbona, GC, Papotti M, Jeantet A, Radice E. Secondary and tertiary hyperparathyroidism: Causes of recurrent disease after 446 parathyroidectomies. *Annals of Surg.* 2001; 233: 65–69
18. Gross ND ,Weissman JL , Choen JI . The diagnostic utility of computed tomography for preoperative localization in surgery for hyperparathyroidism. *Laryngoscope* 2004; 2: 227 – 31
19. Pasiaka JL, Parsons LL (2000) A prospective surgical outcome study assessing the impact of parathyroidectomy on symptoms in patients with secondary and tertiary hyperparathyroidism. *Surgery.* 2000; 128:531–539
20. Costa-Hong V, Jorgetti V, Gowdak LHW, Moyses RM, Krieger EM, De Lima JJ., et al. Parathyroidectomy reduces cardiovascular events and mortality in renal hyperparathyroidism. *Surgery.* 2007; 142:699–703
21. Lorenz K, Ukkat J, Sekulla C, Gimm O, Brauckhoff M, Dralle H. Total parathyroidectomy without autotransplantation for renal hyperparathyroidism: experience with a qPTH-controlled protocol. *World J Surg.* 2006; 30:743–751
22. Stracke S, Jehle PM, Sturm D, Schoenberg MH, Widmaier U, Beger HG, et al. Clinical course after total parathyroidectomy without autotransplantation in patients with end-stage renal failure. *Am J Kidney.* 1999; 33:304–311
23. He Q, Zhuang D, Zheng L, Fan Z, Zhou P, Zhu J, et al. Total parathyroidectomy with trace amounts of parathyroid tissue autotransplantation as the treatment of choice for secondary hyperparathyroidism: a single-center experience. *BMC Surg.* 2014; 5:14:26
24. Ohe MN, Santos RO, Neves MC, Carvalho AB, Kunii IS, Abrahão M, et al. Autotransplant tissue selection criteria with or without stereomicroscopy in parathyroidectomy for treatment of renal hyperparathyroidism. *Braz J Otorhinolaryngol.* 2014;80(4):318-24
25. Tominaga Y, Uchida K, Haba T, Katayama A, Sato T, Hibi Y, et al. More than 1,000 cases of total parathyroidectomy with forearm autograft for renal hyperparathyroidism. *Am J Kidney Dis.* 2001;38 4 Suppl. 1:S168-71
26. Jofré R, López Gómez JM, Menárguez J, Polo JR, Guinsburg M, Villaverde T, et al. Parathyroidectomy: whom and when? *Kidney Int Suppl.* 2003;(85):S97-100.
27. Badiu C, Stanescu B, Chirugiendocrinacervicala. Bucuresti:

- Editura Academiei Romane; 2005
28. Tarcoveanu E, Niculescu D, Moldovanu R, Cotea E, Vasilescu A, Danila N, et al. Surgical treatment of hyperparathyroidism, *Chirurgia*. 2009;104(5):531-44. Romanian
  29. Diaconescu MR, Glod M, Diaconescu S, Patologiachirurgicala a glandelor paratiroide. Iasi :Performantica ; 2009
  30. Llach F, Velasquez Forero F, Secondary hyperparathyroidism in chronic renal failure: pathogenic and clinical aspects, *Am J Kidney Dis*. 200;38(5 Suppl 5):S20-33
  31. Rudser KD, de Boer IH, Dooley A, Young B, Kestenbaum B., Fracture risk after parathyroidectomy among chronic hemodialysis patients, *J Am Soc Nephrol*. 2007;18(8):2401-7
  32. Duffy A, Schurr M, Warner T, Chen H., Long-term outcomes in patients with calciphylaxis from hyperparathyroidism, *Ann Surg Oncol*. 2006 ;13(1):96-102
  33. Trunzo JA, McHenry CR, Schulak JA, Wilhelm SM. Effect of parathyroidectomy on anemia and erythropoietin dosing in end-stage renal disease patients with hyperparathyroidism. *Surgery* 2008;144:915-8.
  34. Yasunaga C, Nakamoto M, Matsuo K, Nishihara G, Yoshida T, Goya T, Effects of a parathyroidectomy on the immune system and nutritional condition in chronic dialysis patients with secondary hyperparathyroidism, *Am J Surg*. 1999; 178: 332-336
  35. Khajehdehi P, Ali M, Gebory FA, Henry G, Bastani B, The effects of parathyroidectomy on nutritional and biochemical status of hemodialysis patients with severe secondary hyperparathyroidism, *J Renal Nutr*. 1999; 9:186-191