

How I Do It

Chirurgia (2015) 110: 268-274
No. 3, May - June
Copyright© Celsius

Laparoscopic Mesh Sacropexy for Voluminous Rectocele

R. Vizeteu, N. Iordache, D. Andrei

Department of General Surgery, "St. John" Hospital, Bucharest, Romania

Rezumat

Sacropexia cu meșă pentru rectocel voluminos pe cale laparoscopică

Rectocelul reprezintă o herniere a rectului printr-un defect al fasciei rectovaginale care apare ca o bombare la nivelul peretelui vaginal posterior. Tratatamentul chirurgical cuprinde numeroase procedee care se pot efectua prin patru tipuri de abord: transvaginal, transanal, transperineal și transabdominal. Cazurile de rectocel voluminos sunt rare și reprezintă de multe ori o provocare chirurgicală. Doar două dintre cele patru tipuri de abord s-au dovedit fezabile pentru rezolvarea unui rectocel voluminos, cel transvaginal și cel transabdominal. Autorii propun pentru rezolvarea acestor cazuri tehnica sacropexiei cu meșă realizată prin abord laparoscopic. Procedeu presupune decolarea retrorectală și separarea rectovaginală până la planșeul pelvin, urmate de o rectovaginopexie la promontoriu folosind o meșă de polipropilenă cu 2 brațe în formă de Y. Unul dintre brațele meșei este fixat la peretele rectal anterior cu patru fire de sutură iar celălalt braț este suturat la peretele vaginal posterior. Capătul meșei este fixat la promontoriu. Se realizează astfel ancorarea rectului prolapsat și a fundului de sac posterior vaginal la ligamentul sacrat, meșă de polipropilenă substituind fascia rectovaginală deteriorată. Principalul simptom care a fost urmărit, dificultatea la defecație, s-a ameliorat semnificativ, nicio pacientă nemaifiind nevoită să

recurga la manevre digitale pentru evacuarea rectului. Rezultatele bune ale experienței inițiale ne fac să credem că acest procedeu reprezintă o soluție tehnică atractivă pentru rezolvarea acestor cazuri dificile.

Cuvinte cheie: rectocel voluminos, sacropexie cu meșă, laparoscopie

Abstract

The rectoceles represent a protrusion of the rectum through the rectovaginal fascia, which appears as a bulge in the posterior vaginal wall. Surgical treatment includes many procedures which can be performed by four types of approaches: transvaginal, transanal, transperineal and transabdominal. Voluminous rectoceles cases are rare and often represent a surgical challenge. Only two types of approaches are proved to be feasible for the treatment of a voluminous rectocel, the transvaginal and the transabdominal approaches. To resolve these cases, the authors propose laparoscopic mesh sacropexy. The procedure implies retrorectal dissection and rectovaginal dissection down to the pelvic floor, followed by a rectovaginopexy to the sacral promontory, using an y-shaped polypropylene mesh. One arm of the mesh is fixed to the anterior rectal wall using four stitches and the other arm is sutured to the posterior vaginal wall. The end of the mesh is fixed to the promontory. Thus, the anchoring of the prolapsed rectum and the posterior vaginal fornix to the sacral ligament is achieved, the damaged rectovaginal fascia being substituted by the polypropylene mesh. The main symptom that was tracked, difficulty in defecation, was significantly improved, none of the patients needed any longer digital maneuvers to empty the rectum. The good results of the first experience

Corresponding author:

Radu Vizeteu, MD, PhD
Department of General Surgery
"St. John" Hospital, Bucharest, Romania
13 Vitan Barzesti, 042122
E-mail: rvizeteu@yahoo.com

make us believe that this procedure is an attractive solution to resolve these difficult cases.

Key words: voluminous rectocele, mesh sacropexy, laparoscopy

Introduction

The rectocele is the result of the weakness that appears, for various reasons, in the rectovaginal fascia (1,2). Classical procedures for rectocele correction (posterior colporrhaphy, levator ani muscles plasty), are followed by dyspareunia, especially when the rectocele is voluminous. Repair of the rectovaginal fascia using mesh plasty, eliminates this important disadvantage, especially in sexually active women (3).

We considered that the experience of the rectal mobilization acquired in oncological interventions could help us to approach this type of pathology.

We intended to realize a laparoscopic procedure to resolve the rectocele, using polypropylene mesh pexy.

The reduced number of cases doesn't allow us to present statistically significant data, though, postoperative evolution and recorded very good results in the short term, determine us to believe that this laparoscopic procedure represents an attractive alternative for resolving voluminous rectocele.

The rectocele – anatomy and pathophysiology

The rectocele appears due to the rectovaginal fascial defects through which the rectum herniates during defecation effort or orthostatism.

The rectovaginal fascia is a fibromuscular structure, situated between rectum and the vaginal wall and constituted by collagen fibers, elastic fibers and smooth muscle tissue (X1). Three points of anchoring to solid structures provide the strength to prevent the rectum to prolapse into vagina. Superiorly, the rectovaginal fascia is attached, at the level of the uterine cervix, to the complex formed by the cardinal ligament and the sacrouterine ligament. In the middle part, it fuses with the levator ani muscle fibers and their fascia. Inferiorly, the rectovaginal fascia is attached to the perineal body. The obstetrical trauma produces injuries to the pelvic structures. Elongations, disruptions and disinsertions may occur in the rectovaginal fascia. These injuries produce over time the appearance of the rectocele. Hence the importance granted to the identification and the reparation of these lesions. When disinsertion of the cranial attachment occurs, a high voluminous rectocele appears. This is the anatomopathological condition in which the procedure we present we think is useful.

Preoperative evaluation

Clinical examination is essential for the evaluation of the patients with rectocele.

A careful anamnesis must identify the reasons patients address to doctor and also the etiopathogenic factors involved

in rectocele's occurrence. Symptoms can be grouped in three categories: vaginal, linked to defecation act and linked to sexual activity. These symptoms combine in different degrees, but without an existing correlation between rectocele's dimensions and severity of the symptomatology. Most often, in the beginning, patients complain about a perineal sensation of pressure and they observe a bulge in the posterior vaginal wall. The symptomatology is more pronounced at the end of a day with prolonged periods of orthostatism. In case of a voluminous rectocele, which exceeds the vaginal introitus, erosions and ulcerations of the vaginal mucosa may even occur.

Rectal protrusion through the posterior vaginal wall, leads to defecation disorders. Symptoms are various: constipation, evacuation difficulty, incomplete emptying sensation. In cases with big defects, patients use to reduce the rectocele by digital vaginal maneuvers in order to achieve rectal ampulla emptying.

Voluminous rectocele also associates with sexual dysfunction due to the increase of the vaginal caliber following progressive weakening of the supporting elements.

The determining factor in the appearance of the rectocele is the obstetrical trauma. From the medical history of these patients we find out about multiple births, laborious births (fetal macrosomia, use of forceps), episiotomies with vicious scarring.

Also by anamnesis, other factors with contributory role in the development of the rectocele can be identified: obesity, chronic constipation, chronic cough. Combating these factors (quitting smoking, weight loss) is recommended especially in the prospect of surgery. Other factors that can favor the occurrence and development of the rectocele are: collagen diseases, old age and estrogen deficiency that characterize postmenopausal women.

Local examination confirms the diagnosis by identifying the rectocele which appears as a bulge in the posterior vaginal wall. The digital vaginal examination performed separately, but also combined with the digital rectal examination, has to assess the size of the defect, which extends sometimes to the posterior vaginal fornix, the condition of the perineal body, the trophicity of the vaginal mucosa and eventually associated pelvic support defects (cystocele, uterine prolapse).

In most cases, a complete clinical examination is enough to establish a correct diagnosis. The imaging examinations, such as defecography or even rectal MRI in dynamics, are laborious, but may be useful in those cases where patient's suffering is not justified by the local examination findings. Colonoscopy is performed in all the cases in order to exclude concomitant colonic diseases.

Indications

The described procedure was performed only in the case of patients with voluminous rectocele who presented defecation disorders. For the patients who presented the other types of symptoms, vaginal and sexual, but without evacuation difficulties, the rectocele was repaired by vaginal approach.

The goal of the intervention is the restoration of the local anatomy and particularly, the reestablishment of the integrity of the rectovaginal fascia. In this procedure, a mesh will sub-

stitute the damaged rectovaginal fascia, in order to offer support to the anterior rectal wall.

Preoperative preparation

When the local examination finds an atrophic vaginal mucosa, due to low estrogenic impregnation, local application of estrogen is indicated, before surgery.

Being a pelvic intervention, to facilitate the laparoscopic approach, it is mandatory to have an appropriate preoperative preparation of the colon. This includes specific diet, with reduced fiber content, which must be followed for 5-7 days before surgery, as well as purgative medication that provides mechanical cleaning of the colon. Doing so, we can easily release the pelvis from bowels, thus obtaining the required space for a convenient deployment of the laparoscopic gestures. Bowel preparation, along with the patient positioning on the operating table, the positioning of the operating table and a good relaxation of the abdominal muscles are conditions for completion of this intervention laparoscopically.

Antibiotic and thromboembolic complications prophylaxis is achieved according to usual protocols.

Operating room set-up

The patient is placed in supine position on the operating table, with the right arm alongside the body and the left arm at a right angle. After orotracheal intubation, an urinary catheter is mounted.

The surgical team contains three members. The surgeon and the first assistant stand on the right side of the patient and the second assistant stands on the other side.

The first part of the intervention doesn't require special instruments, the dissecting hook and scissors, both connected to monopolar current, and the usual graspers being sufficient to realize the dissection. To complete the montage, we need though, a laparoscopic needle holder, a knot pusher and a tacker.

Additionally, if we intend to associate a sigmoidectomy, the availability of an advanced electro-surgery system or an ultrasonic dissector, represents a real advantage for a rapid and safe treatment of the sigmoid vessels.

Pneumoperitoneum is created using Veress needle or the open technique, establishing a working pressure of 12 mm Hg.

Trocars placement is basically similar to the colorectal interventions (Fig. 1). Optical trocar is placed on the midline, above the umbilicus. Operating trocars are on the right midclavicular line, a 5 mm trocar at the level of the umbilicus and a 10 mm trocar, 6-8 cm caudally to the first one. Also on the median line, above the pubis and on the left midclavicular line, at the level of the umbilicus, another two 5 mm trocars are mounted through which the assistant uses graspers to assure a proper exposure during intervention.

Operative technique

Exposure and exploration

The accomplishment of the operation is conditioned by a

proper exposure of the pelvis throughout the whole intervention. We have already pointed the importance of a good preoperative bowel preparation. The reduced volume of intestinal loops obtained through described measures, is reflected in the easiness with which, gravitational maneuvers (Trendelenburg positioning and right tilting of the operating table) and successive grasping maneuvers of the small intestine loops, greater omentum and transverse colon to the superior quadrants of the peritoneal cavity, assures liberation of the pelvis (Fig. 2).

In the presence of postoperative or inflammatory adhesions, viscerolysis must be performed to assure restoration of the normal anatomical rapports.

Additionally, it is necessary to suspend the uterus, using two stitches passed through the entire anterior abdominal wall and then through uterine insertion of the round ligaments or through uterine fundal myometrium (Fig. 3). The suspension of the uterus is useful not only for removing it from the operative field, but also for a proper exposure of the pelvic excavation, thus facilitating peritoneal incision which will be performed in this place.

Pelvis being thus exposed, an inventory of all modifications which can be encountered in the rectovaginal prolapse, can be performed. It can be observed: the deepness of the Douglas excavation, the rectum which is slipped caudally, following the sacral curvature and also the length of the sigmoid, which is frequently long (Fig. 4).

Dissection of the prolapsed rectum

The first step of the intervention is the opening of the presacral space. To achieve that, it is necessary to expose the meso-sigmoid root, a maneuver in which the prehension exerted by the assistant with the grasper from the left flank, who lifts the

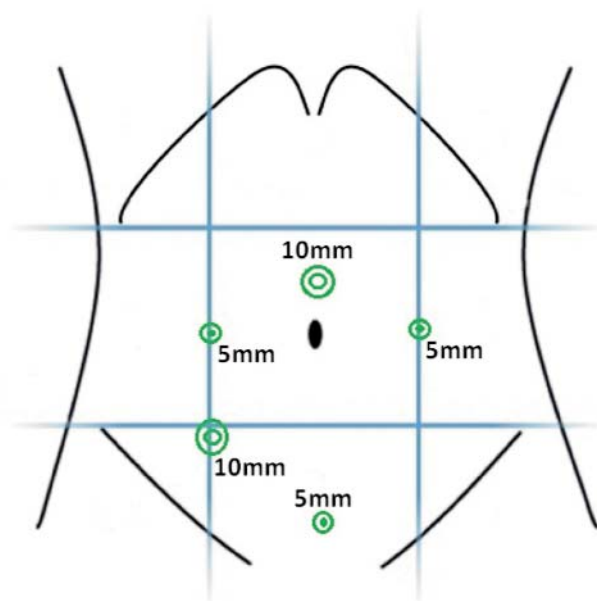


Figure 1. Trocar placement

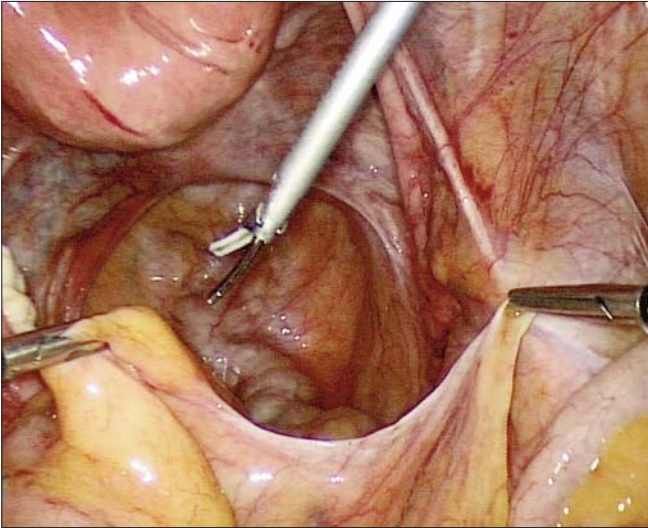


Figure 2. *Releasing the pelvis from intestinal loops*

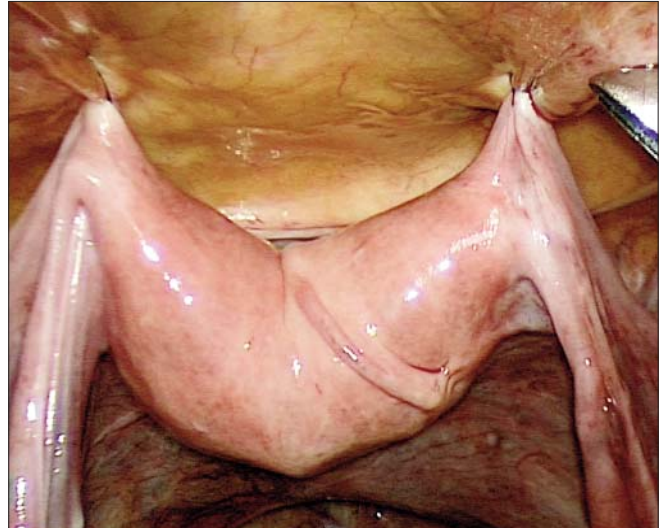

Figure 3. *Uterine suspension*

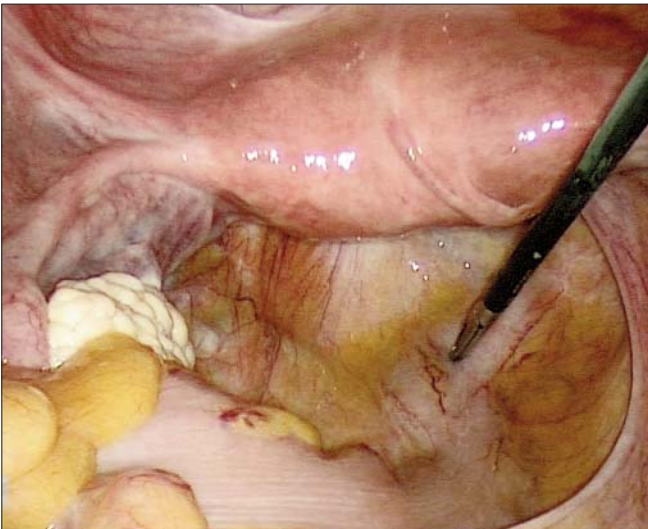


Figure 4. *Deep pouch of Douglas*

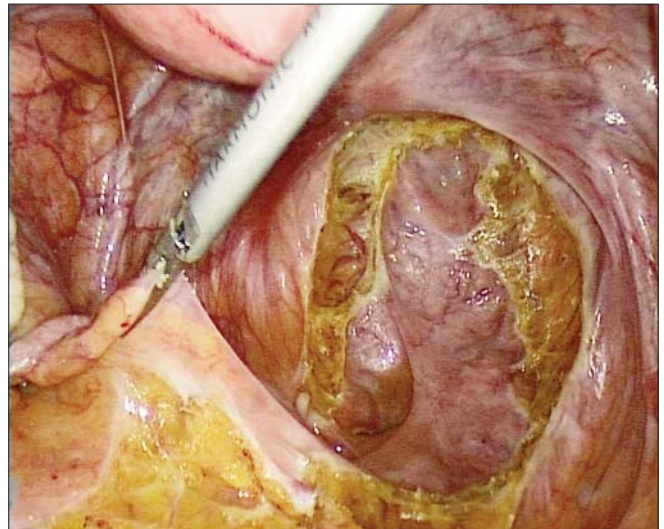


Figure 5. *Peritoneal incision*

mesosigmoid, has a crucial role. Countertraction is assured by the grasper from the surgeon's left hand. The peritoneum is incised anteriorly to the promontory and the presacral space is open, where the space between the presacral fascia and fascia propria of the rectum is revealed. The section of the peritoneum descends on the right side, laterally to the rectum, to the most caudal point of the Douglas excavation, then it has a transverse direction, closer to the vagina than the rectum and then it ascends on the left side of the rectum, thus taking the shape of the letter "U" (4)(Fig. 5). Out of habit I use the hook for dissection, but scissors connected to monopolar current or ultrasonic dissector can also be used.

Posterior dissection advances in the presacral space, an avascular space, being facilitated also by the pneumodissection. Maintaining the dissection in this avascular space, we avoid posterior injury of the superior hypogastric nerve plexus

(especially in the mid part of the sacrum, where it tends to be tractioned by the prehension applied to the rectum), injury of the presacral venous plexus and fascia propria of the rectum anteriorly. Presacral dissection descends caudally to the pelvic floor (Fig. 6).

Further, the dissection is realized anteriorly to the rectum, starting from the peritoneal incision, in the rectovaginal space, as close as possible to the vagina, the anterior wall of the rectum permanently being pushed posteriorly by the operator's left hand grasper (Fig. 7). It is important that anterior dissection of the rectum to descend as caudal as possible, being known that rectal prolapse affects especially the anterior wall and less the posterior wall (5,6,7).

Laterally, depending on the prolapse length, for an easy mounting of the mesh, the upper part of the "lateral rectal wings" can be divided, or it may be considered the possibility

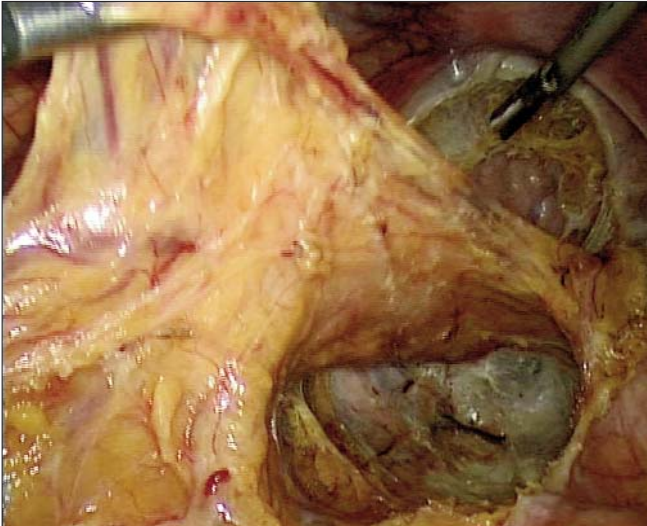


Figure 6. *Dissected presacral space*

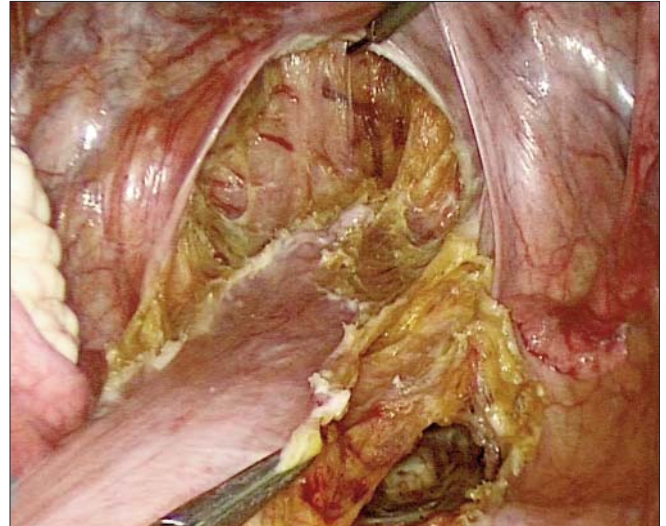


Figure 7. *Prerectal space dissection*

to preserve the right lateral rectal ligament. In this case, it is necessary to create a tunnel in its upper part through which the mesh will be passed from posterior to anterior, in order to be anchored to the anterior rectal wall.

After the dissection of the anterior and posterior rectal wall, the excessive peritoneum that constituted the pouch of Douglas, which is very deep in these cases, is excised (Douglasectomy). This maneuver needs attention in order not to injure the rectal wall and it must assure in the same time the preservation of a peritoneal collar in order to pass the peritonization stitch. Resection of the elongated pouch of Douglas prevents the appearance of ehytrocele.

Montage realization

For suspension, a monofilament polypropylene mesh is used,

measuring 2,5/15 cm, tailored with two arms, measuring about 13 cm each, as shown in the figure below (Fig. 8).

The mesh is introduced through the 10 mm trocar and it is attached first to the promontory, much easier using helical tacks or using stitches passed through the sacral ligament (Fig. 9). We used non-absorbable 2-0 stitch and extracorporeal tying. Regardless of the method we use to fix the mesh, care must be taken in order not to injure the iliac vein laterally and sacral vessels in the midline. Also, it is necessary to assure that the peritoneal incision at this level overcomes cranially the superior edge of the mesh, for this one to be easily covered with peritoneum at the end of the procedure.

The most delicate part of the procedure is the rectal anchoring. The aim is to maintain the rectum in high position, in the pelvic cavity, to prevent its prolapse in orthostatism.

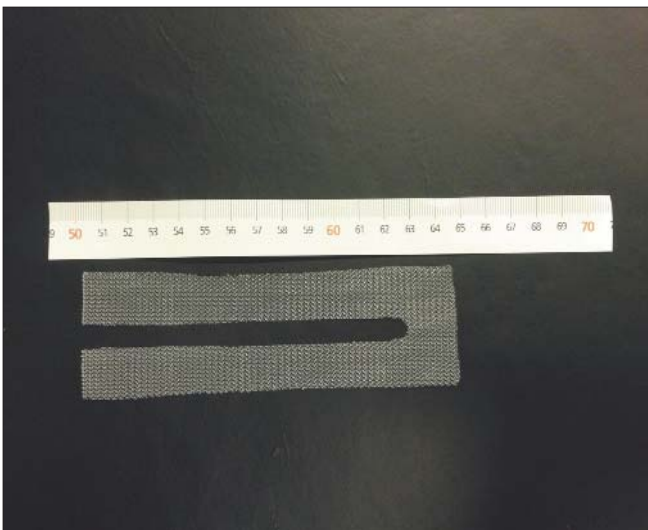


Figure 8. *Mesh tailored on the table*

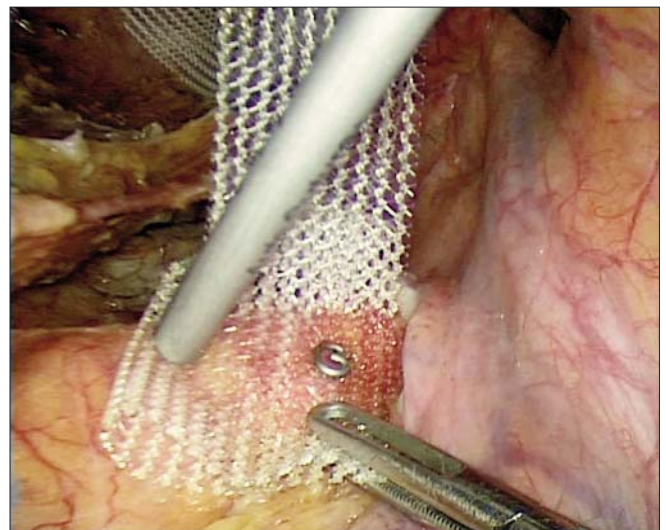


Figure 9. *Promontory fixation*

Therefore, while the rectum is tractioned cranially, the posterior arm of the mesh is lowered to be fixed to the anterior rectal wall. Excessive traction can cause the opening of the anorectal angle, which can cause anal incontinence (5). The mesh is fixed with 3 or 4 non-absorbable stitches, passed with care in order to avoid rectal perforation and tied extracorporeally (Fig. 10). If it exists, excess of the mesh is cut.

Vaginal prolapse is frequently associated in these patients and it contributes to the rectocele development. Therefore, colpexy is required, which is performed with the anterior arm of the mesh (8). This is fixed to the posterior wall of the vagina, performing a colpexy using 2 or 3 non-absorbable stitches as well, tied extracorporeally (Fig. 11).

Pelvic peritonization

Although the main time of the intervention is done, the montage being finished, a special care must be taken further at the pelvic peritonization which concludes the intervention (Fig. 12). A correct peritonization must meet two conditions. The mesh should be covered entirely with peritoneum, being thus situated practically retroperitoneally, to prevent formation of visceral adhesions and eventual erosive complications produced by the mesh. Also, the approximation of the peritoneal edges must be perfect and therefore the distance between stitches should't be too long in order to avoid peritoneal breaches which can present an occlusive potential by engagement of intestinal loops.

Pelvic peritonization is performed using an absorbable monofilament stitch. It starts in the midline with running suture, first on the right, heading cranially. The monofilament stitch allows successive passes through peritoneal edges and allows to be tied in the end, because it can easily glide. The same thing is performed on the left side starting from cranially to the midline, where the stitch is tied with the long end of the first stitch.

Drainage of the neo-pouch of Douglas is optional, in most cases being unnecessary because the intervention is bloodless.

Technical variants

Some surgeons add to vaginorectopexy procedure a sigmoidectomy which would be indicated especially for patients who have a problem with constipation preoperatively. Resection of the sigmoid decreases the likelihood of postoperative constipation as well as providing some cephalad traction on the rectum itself. However, addition of a resection after insertion of a mesh is controversial.

There are also surgeons who perform laparoscopic rectocele repair without mesh; this involves opening the rectovaginal space and dissecting inferiorly to the perineal body. The perineal body is sutured to the rectovaginal septum and rectovaginal fascial defects are identified and closed. The levator ani muscles may be plicated (9).

Postoperative care

Postoperatively, it is recommended to avoid physical efforts for three months, to have a liquid-rich diet to combat constipation, and to have sexual rest for six weeks. An

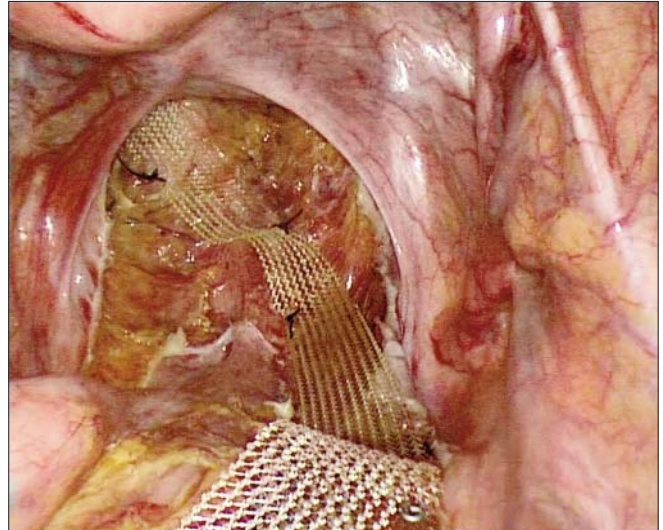


Figure 10. Rectal anchoring

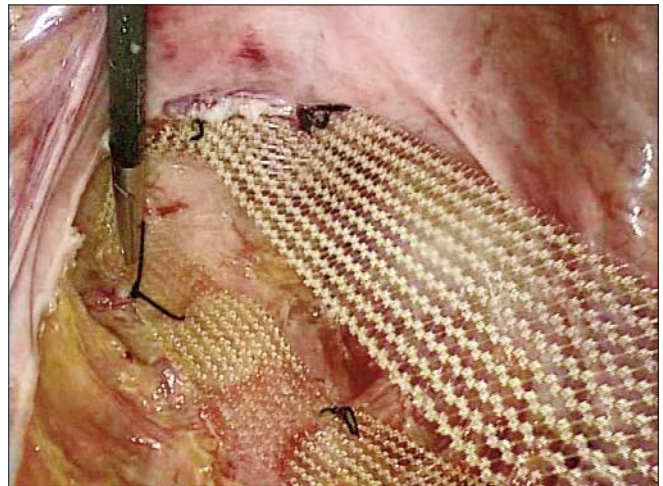

Figure 11. Colpexy

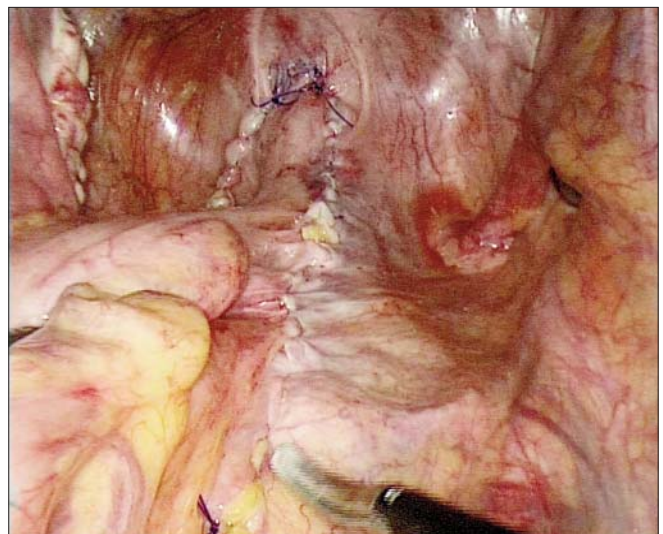

Figure 12. Covering the mesh by peritonization

appropriate tonus of the perineal muscles, especially the levator ani muscles, contributes to the maintenance of a good long-term postoperative result. Therefore, Kegel exercises are indicated after this type of surgery.

Discussion. Results

The rectocele is a condition situated at the border of several surgical specialties, gynecologists, general surgeons and even urologists being involved in its treatment. Each specialty had a different perspective on the patient's suffering, indications and on the surgical treatment. This situation led to the appearance of many surgical procedures and consequently to controversies about optimal approach. Surgical procedures described for the cure of rectocele, can be performed by different approaches: transvaginal, transanal, transperineal and transabdominal.

The transvaginal approach is known by both gynecologists and surgeons, posterior colporrhaphy being the procedure currently used. By midline plication or by purse-string invagination, the reduction of the prolapsed rectal wall is assured, without an exact identification of the rectovaginal fascial defect. Additionally, the suture of the levator ani muscles is meant to reinforce this suture, playing the role of the rectovaginal fascia. Bringing muscular structures from their lateral normal position to the midline, a hypercorrection is frequently obtained, which leads to postoperative dyspareunia. In order to reduce this unpleasant complication, site-specific posterior repair was proposed. Exact identification of the defect through dissection, makes it possible to repair the rectovaginal fascia by re-anchoring it by suturing to the perineal body or to the levator ani muscles. In order to increase the strength of the montage over time, a polypropylene mesh is applied over the rectovaginal fascia. All these technical improvements have made transvaginal approach to be very effective in the surgical treatment of the rectocele.

The classic transanal approach has some limitations regarding both anatomical and technical points of view, which are experienced especially in case of a high rectocele, being generally accredited with poorer results compared with the transvaginal approach. To facilitate the intervention, it has been proposed to use staplers within STARR technique (stapled transanal rectal resection). However, these procedures are not indicated for the high rectocele associated with enterocele.

The transperineal approach is rarely used too, usually in the case of a rectocele with fecal incontinence by anal sphincter defect.

The transabdominal approach is indicated especially to the patients with highly situated defects of the rectovaginal fascia, manifested by rectocele and enterocele.

Based on the experience acquired in the minimally invasive surgery, we have considered that laparoscopic transabdominal approach may be an attractive alternative to the transvaginal approach for solving difficult cases with voluminous rectocele. After retrorectal dissection and rectovaginal separation down to the pelvic floor, a rectovaginopexy is performed to the promontory, using a polypropylene mesh with two arms. A solid recon-

stitution is thus obtained in place of the damaged rectovaginal fascia. A special attention must be given to the tension used in the rectopexy because an excessive cranial traction can open the anorectal angle and may lead to fecal incontinence.

Our experience includes five patients in which we used this procedure for voluminous rectocele. The surgical indication was determined by the defecation difficulties, in all the cases patients using to digitally reduce the rectocele in order to succeed in having evacuation. The short period of postoperative follow-up and the small number of cases doesn't allow us to present statistically significant data, but early results are promising.

All the interventions were completed laparoscopically. The advantages of the minimally invasive approach were revealed by quick recovery and short hospitalization. Local examination after surgery revealed anatomical correction of the rectocele in all the cases.

Due to the correction of the voluminous rectocele, constipation, the main complain of this disease, was not a problem anymore. A significant decrease in vaginal discomfort and no dyspareunia problem, were the reason of full patient's satisfaction during the first follow-up year.

We didn't record recurrences of the rectocele, but only three patients completed one year after surgery. We didn't record mesh-related complications: infections, erosions.

Conclusions

These good results obtained in our first experience make us believe that this technique is an attractive solution for these challenging cases. We intend to continue this study in order to obtain more consistent data to evaluate this surgical procedure.

References

1. Richardson AC. The rectovaginal septum revisited: its relationship to rectocele and its importance in rectocele repair. *Clin Obstet Gynecol* 1993;36:976-83.
2. Richardson AC. The anatomic defects in rectocele and enterocele. *J Pelvic Surg* 1995;1:214-21.
3. Lyons TL, Winer WK. Laparoscopic rectocele repair using polyglactin mesh. *J Am Assoc Gynecol Laparosc* 1997;4:381-4.
4. Mandache F. Rectopexia la promontoriu pe cale abdominala (Orr). In: Mandache F. *Chirurgia rectului*. Bucuresti: Editura Medicala; 1971. p.432-435.
5. Wattiez A, Canis M, Mage G, Pouly JL, Bruhat MA. Promontofixation for the treatment of prolapse. *Urol Clin North Am* 2001 ;28: 151- 7.
6. Maggiori L, Bretagnol F, Ferron M, Panis Y. Laparoscopic ventral rectopexy: a prospective long-term evaluation of functional results and quality of life. *Techniques in Coloproctology*. 2013 Jan 23.
7. Murad-Regadas SM, Regadas FS, Rodrigues LV, Fernandes GO, Buchen G, Kenmotsu VT. Management of patients with rectocele, multiple pelvic floor dysfunctions and obstructed defecation syndrome. *Arq Gastroenterol*. 2012 Apr-Jun;49(2):135-42.
8. Hong L, Li HF, Sun J, Zhu JL, Ai GH, Li L, Zhang B, Chi FL, Tong XW. Clinical observation of a modified surgical method: posterior vaginal mesh suspension of female rectocele with intractable constipation. *J Minim Invasive Gynecol*. 2012 Nov-Dec;19(6):684-8.
9. Paraiso M FR, Falcone T, Walters M D. Laparoscopic surgery for enterocele, vaginal apex prolapse and rectocele. *Int Urogynecol J*. 1997;8:146-152.