

General Reports

Chirurgia (2014) 109: 584-589
No. 5, September - October
Copyright© Celsius

Peripheral Nerve Allografting - Why and How?

S.C. Bădoiu^{1,2}, I. Lascăr^{2,3}, D.M. Enescu^{2,4}

¹Department of Plastic Surgery, "Agrippa Ionescu" Emergency Hospital, Bucharest, Romania

²"Carol Davila" University of Medicine and Pharmacy, Bucharest, Romania

³Department of Plastic Surgery, Clinical Emergency Hospital, Bucharest, Romania

⁴Department of Plastic Surgery, "Grigore Alexandrescu" Hospital, Bucharest, Romania

Rezumat

Allogrefele de nervi periferici - când și cum?

Autorii prezintă, pe scurt, metodele de reconstrucție a defectelor de nervi periferici. Dintre acestea, autorii detaliază reconstrucția cu alogrefe de nervi periferici și modalitățile de a obține toleranța imună a organismului gazdă. Autorii subliniază ideea că, este mai bine să se obțină alogrefe non-antigenice decât să se suprimă imunitatea organismului receptor. În continuare, autorii prezintă metodele de denaturare a alogrefelor de nervi periferici cu scopul de a le face non-antigenice și insistă asupra necesității de a dezvolta metode aplicabile în clinica umană. Autorii concluzionează că reconstrucția defectelor de nervi periferici cu alogrefe de nervi denaturate oferă rezultate excelente și această metodă trebuie extinsă și la pacienții umani.

Cuvinte cheie: reconstrucția de nervi, grefe de nervi periferici, alogrefe de nervi periferici, denaturarea alogrefelor de nervi, imunosupresie, toleranță imună

Abstract

The authors briefly present the methods of reconstruction of peripheral nerve gaps. Of these methods, the reconstruction with nerve allografts is reviewed mainly in what concerns the ways to achieve host tolerance for the allograft. The authors underline the fact that, for the recipient it is better to suppress the graft antigenicity than to suppress the host immune response. Further, the authors present the most important methods to denaturate a nerve allograft in order to make it non-antigenic and insist upon developing methods that can be used in human beings. The authors conclude that reconstruction of nerve defects with peripheral nerve allografts is a very rewarding method that should be extended in clinical practice.

Key words: nerve reconstruction, peripheral nerve grafts, nerve allografts, denaturing nerve allografts, immunosuppression, immune tolerance

Corresponding author:

Silviu Constantin Bădoiu, MD PhD
Plastic, Hand and Microsurgeon, Lecturer at
the Anatomy Department
"Agrippa Ionescu" Emergency Hospital
No. 7, arh. Ioan Mincu street, 1st district
Bucharest, Romania
E-mail: silviubadoiu@yahoo.co.uk

Introduction

Bridging peripheral nerve gaps is a common procedure in clinical practice. Hand surgeons, plastic surgeons, orthopedic surgeons, microsurgeons do it on a daily basis (1). The gold standard concerning the functional result is to reconstruct the nerve defect with peripheral nerve autografts (1). This method has several drawbacks:

- limited donor sites (1,2);
- sacrificing sensibility in the territory of the donor

- nerve, with hipoesthesia and paresthesia (1,2,3);
- scars (1,2);
- in large defects, the peripheral nerve autografts might not be enough (1,2,3,4);
- prolonging the duration of the surgical procedure (5).

In order to avoid the inconveniences mentioned above, doctors and scientists have imagined alternative methods of reconstruction of peripheral nerve defects (3,5,6).

Reconstruction with autologous tissues, other than peripheral nerve

Many tissues were proposed for the reconstruction of peripheral nerve defects: denaturated skeletal muscle (7,8), veins (9), arteries (9), autologous Schwann cells (10,11,12), adipose or bone marrow tissue-derived stem cells (13,14), tendon (15,16), combinations of autologous tissues (17).

Reconstruction of peripheral nerve gaps with autologous denaturated muscle graft

The denaturated muscle provides a longitudinally oriented scaffold, consisting of the basal lamina of the striate muscle cells. This structure acts like a guide for the regenerating axons (7).

During the first experiments, autologous non-denaturated muscle was used. The axonal regeneration had to be preceded by the natural degeneration of the muscular fibres. The results were poor.

The denaturation of the skeletal muscle has been done in many different ways, the commonest methods being: injecting the muscle with a local anesthetic (18), freeze-thawing of the muscle (19) or a combination of these two methods (20). The purpose of muscle denaturation is to obtain an acellular muscle graft (Fig. 1). The axonal growth through a denaturated muscle graft is good only for short defects (7,8). The results are good for sensitive nerves. For motor or mixed peripheral nerves, the functional results with autologous denaturated muscle grafts are poor when compared with a

peripheral nerve autograft (8). There is another drawback for the method, consisting in the need of 24 hours before the peripheral nerve reconstruction, in order to prepare the skeletal muscle graft (18,19). In conclusion, the method has limited clinical usage and only applies for small peripheral nerve gaps (8).

Reconstruction of peripheral nerve gaps with veins

Nowadays, the method is currently used to repair sensitive nerve gaps in hand surgery. The autologous vein graft might be used for reconstruction of a sensitive nerve as an emergency procedure (21), as a primary repair procedure (22) or as a secondary repair procedure (23). The authors of the present article have been using this method to primary reconstruct common digital nerves and digital nerves at the level of the hand and fingers. The longest defect reconstructed by the authors was 4 cm. The results of the authors and in the literature are good, comparable with those of reconstruction with a peripheral nerve autograft. The advantages are: avoiding the sacrifice of other sensitive nerves, less scars, simple and short surgical procedure (to harvest the autologous veins from the subcutaneous rete at the wrist level or on the dorsum of the hand) (22).

The method cannot be used for motor or mixed peripheral nerves (23).

Reconstruction with synthetic conduits

Historically and experimentally, the synthetic conduits used were non-absorbable (silicone) (Fig. 2) or biodegradable (24,25). Of the absorbable conduits, only three have the Food and Drug Administration approval for clinical use in humans (25,26): collagen tubes, polyglycolic acid tubes and caprolactone tubes. The main utility is for sensory nerve defects smaller than 3 cm. The caprolactone tubes "are equivalent in results to autografts" (26). Collagen conduits and polyglycolic acid tubes seem to offer inferior results, when compared to peripheral nerve autograft (26). An experimental

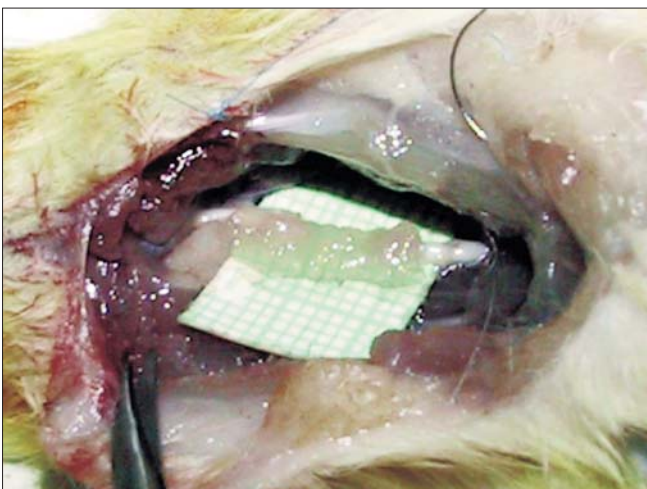


Figure 1. Reconstruction of a rat sciatic nerve gap with autologous denaturated muscle graft

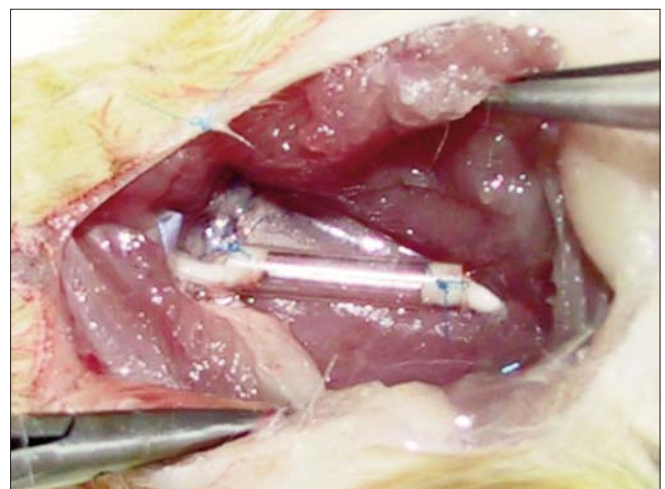


Figure 2. Reconstruction of a rat sciatic nerve gap with silicone tube

study regarding commercially available biodegradable tubes showed best results with caprolactone tubes, fair results with collagen conduits and poor results with polyglycolic acid tubes (27). This study was conducted on rats and evaluated the functional motor recovery. The advantages of biodegradable conduits is their availability just like the teflon prostheses for vascular surgery. Using a synthetic tube spares a sensory nerve from being used as autograft. The disadvantages are their limited use for segmental nerve defects smaller than 3 cm and the unacceptable functional results in reconstruction of motor nerves and mixed nerves (26,27). We may conclude that synthetic tubes are a good alternative to peripheral nerve autografts in human clinic only for small defects of sensitive nerves (most often digital nerves).

Reconstruction with peripheral nerve allografts

This method has clinical applicability in humans (3,28). Nerve allograft acts as a scaffold for the axonal regeneration of the recipient patient (1,2,3,4,5,6,29,30,31,32,33,34). It seems that the first reported nerve allograft in humans was performed in 1885 by Albert (4) who used a cadaver nerve allograft to reconstruct a postexcisional median nerve defect. In 1973 Pollard et al. performed the first experimental study, using a nerve allograft to reconstruct a 4 cm sciatic nerve defect in immunosuppressed rats. The immunosuppression was therapeutically achieved with azathioprine (Imuran); the regeneration through the graft was assessed clinically, electrophysiologically, and histologically (4).

As stated in the introduction of the present article, the gold standard in reconstructing peripheral nerve defects is the peripheral nerve autograft, because one replaces the “missing” tissue with the very same type of autologous tissue. The routine is to use sensitive peripheral nerves such as: the sural nerve, the lateral antebrachial cutaneous nerve, the medial antebrachial cutaneous nerve etc. There are situations when the destruction involves several peripheral nerves (e.g. brachial plexus lesions, mangled extremities etc.); in such cases there are not enough autologous peripheral nerves to be harvested. Such extensive nerve injuries are the main stimulus for scientific research in order to identify the most suitable and cheap alternative method of reconstruction of peripheral nerve gaps (6). The other reason (to find an alternative method) is the morbidity associated with the harvest of an autologous peripheral nerve (that is to be used as an autologous graft): scars, hypoesthesia, disesthesia, neuroma etc (3). From this perspective, it seems that “the cadaveric nerve allograft provides an unlimited graft source without the morbidities associated with autograft reconstruction” (6). The peripheral nerve allograft is to be rejected if used like an autograft. There are two possibilities to avoid the rejection of the allograft: to suppress the recipient immune response or to denaturate the allograft in order to make it non-antigenic.

The suppression of the host immune response

Immunosuppression must provide tolerance of the recipient for the allograft, without any impediment on the axonal growth

through the allograft (3,28). In peripheral nerve “allografting” the immunosuppression is only temporary, unlike the situation in solid organ transplantation and in composite tissue transplantation (3,28). Six months after the passage of the regenerating axons through the allograft, the immunosuppression is stopped (3,28). In theory, the axonal regeneration speed in optimal conditions, after direct nerve coaptation is 1 mm/day. In most cases, a good regeneration speed is an inch per month (35). We can speculate that, through the nerve allograft the regeneration is even slower. Taking this into consideration, for a 5 cm defect, the regenerating axons need at least 2 months in order to cross the allograft. Following that, the period of immunosuppression is minimum 8 months (in most cases it is about 1 year). It is a short period when compared with the indefinite time of immunosuppression for solid organ transplantation or for hand transplantation; but it is long enough for the patient to be exposed to some of the risks of immunosuppressive therapy, such as: opportunistic infections (herpes viruses, cytomegalovirus, Epstein-Barr virus, Candida, Aspergillum, Pneumocystis) (36,37), post-transplant diabetes mellitus (37,38), pharmacologic toxicity (renal, neurological, gastrointestinal) (37) and other adverse reactions that occur if the immunosuppressive period is longer, such as malignancies (skin cancers and non-Hodgkin lymphomas refractory to chemotherapy) (37,39). The most popular pharmacologic agent used for immunosuppression in hand transplantation and in nerve allografting is Tacrolimus (FK 506) (40). Although it seems to have stimulating effect on the axonal regeneration and neuroprotective properties, it has potentially severe adverse effects (40,41).

The denaturation of the peripheral nerve allograft

It is common knowledge that immunosuppression may cause many adverse reactions. That is why, a good alternative is to denaturate the peripheral nerve allograft, in order to make it non-antigenic. The denaturated allograft must permit the nerve’s regeneration (6).

Historically, several protocols for peripheral nerve allograft denaturation were used such as: irradiation, alcohol denaturation, lyophilisation, freeze-thawing, cold-preservation, detergent processing, combined methods. Most of them have only experimental utility.

Denaturation of peripheral nerve allograft by irradiation.

This method has been reported in the early ‘70s. It seems that high dose irradiation is much more effective than low dose irradiation, in what concerns the process of decreasing the antigenicity of the peripheral nerve allograft. But when compared with the peripheral nerve autograft, the regeneration through irradiated allograft is “less successful” (42). Regeneration through irradiated allograft is poorer than through the allograft combined with host immunosuppression (42,43).

Alcohol denaturation of the peripheral nerve allograft.

Alcohol produces the denaturation of proteins and alteration of the structures that have proteins. Peripheral nerve allografts denaturated with alcohol have been used in experi-

mental studies and have only historical interest. The axonal regeneration through this type of grafts is inefficient when compared with the regeneration through peripheral nerve autografts and through peripheral nerve allografts in an immunosuppressed host (44).

Lyophilisation of peripheral nerve allografts

Lyophilisation of the nerve allografts has been reported by Weiss, in 1943. This method consists in freeze-drying of the nerve allograft. As single method of denaturation of a peripheral nerve allograft has been used only experimentally. During the last three decades it has been used in combination with irradiation or with chemical decellularization of the peripheral nerve allograft. It seems to be a good method to preserve a pre-denaturated nerve allograft (45).

Freeze-thawing peripheral nerve allografts

There are different protocols for freeze-thawing peripheral nerve allografts: freezing at - 40 degrees centigrade (46) and thawing at +20 degrees centigrade, freezing at -196 degrees centigrade in liquid nitrogen (with or without adding a cryoprotectant) (47) and thawing at +20 degrees centigrade, etc. This method of nerve pre-denaturation has been used mostly experimentally (29,46,47). Some conclusions could be drawn:

- the longer the freezing, the lesser the immune response elicited against the graft (46);
- the longer the freezing, the fewer graft rejection events (46);
- regeneration through a freeze-thawed nerve allograft is delayed when compared with a nerve autograft (46,47);
- grafts pretreated by controlled freezing and then thawing support axonal regeneration only for short distances (46,47);
- revascularization of the freeze-thawed graft is delayed and less effective than revascularization of an autograft (27,46,47).

This pre-denaturation method is useful when combined with other denaturation methods of peripheral nerve allografts and needs further research (47).

Cold preservation of peripheral nerve allografts

Cold preservation of peripheral nerve allografts is achieved by immersing the nerve grafts in Wisconsin solution at 5 degrees centigrade.

Increasing the time of preservation has some clear consequences:

- decreasing the immune response of the host versus the nerve allograft (46);
- decreasing the peripheral nerve allograft rejection (46);
- improving nerve regeneration (46) after 4 weeks of cold preservation (29);
- after 26 weeks of criopreservation the peripheral nerve allograft elicited no immune response from the host and no graft rejection takes place (46).

But regeneration through nerve allografts preserved

under cold is inferior to autografts (29,30,46).

The benefits of cold preservation of nerve allografts seem to be: the possibility to transport nerve allografts between medical centers (29), transforming an emergency peripheral nerve reconstruction into elective surgery (29,46), the combination of cold preservation of the nerve allograft with host immunosuppression (29).

Detergent processing of peripheral nerve allografts

It is also called chemical decellularization of peripheral nerve allografts. All denaturation methods aim to lower the antigenicity of the nerve allograft, but with preservation of the endoneurial tubes as a scaffold for the regenerating axons. Many protocols for chemical denaturation are known, using substances as: sodium deoxycholate, Triton X-100, deionized water, sulfobetaine-10 (SB-10), Triton X-200, sulfobetaine-16 (SB-16) (5). The newer methods of chemical decellularization use less aggressive substances that do not alter the endoneurial tubes and the regeneration is improved. It seems that the axonal regeneration is better through peripheral nerve allografts chemically denaturated when compared to regeneration through peripheral nerve allografts thermally denaturated (5). For the reconstruction of sciatic nerve gaps in rats, detergent-processed allografts are similar to isografts at 6 weeks postoperatively (5).

Chemically decellularized nerve allografts may offer a good alternative for reconstruction of peripheral nerve gaps in experimental studies, but are not yet used in human clinical practice.

Combined methods of denaturation of peripheral nerve allografts

There are many combined methods of denaturation of peripheral nerve allografts and most of them have only experimental usage. For the moment, there is only one product (commercially available) consisting of a denaturated nerve allograft (through combined methods) that is used in human clinical practice. The product is called Avance® Nerve Graft. Processing of the human peripheral nerve allografts involves the use of proprietary physiological buffers, enzyme and surfactants; the product is sterilized using gamma irradiation (48). The first results in clinical practice were published in December 2012 in Journal of Hand Surgery; the article includes outcome data for 51 peripheral nerve repairs (48).

Reconstruction with peripheral nerve xenografts

This method has been used only experimentally, on rats and rhesus monkeys (49,50,51).

Combined methods

The principle of the most accepted combined methods is to use a conduit filled with autologous Schwann cells or a conduit filled with autologous stromal(stem) cells (52,53).

Conclusions

The gold standard for reconstruction of peripheral nerve gaps is the peripheral nerve autograft.

In situations with extensive lesions of peripheral nerves or multiple peripheral nerves damaged there is not enough peripheral nerve autograft for the reconstruction. That is why an ideal alternate method of reconstruction has been sought.

Using peripheral nerve allografts is a very promising method of reconstruction of peripheral nerve gaps because the grafts are available (harvested from human cadavers) and the results of reconstruction are comparable to the results of the gold standard in reconstruction. Whether the allograft is processed or the host is immunosuppressed, the functional recovery is good and the autologous peripheral nerves are spared (and further sensitive or motor deficits are avoided).

During the last 2 years, peripheral nerve allografts have been included in clinical studies that showed good outcomes of the reconstruction.

Based on the medical literature, it is the authors' opinion that reconstruction of nerve defects with peripheral nerve allografts is a very rewarding method that should be extended in clinical practice.

Acknowledgments

This paper is partially supported by the Sectoral Operational Programme Human Resources Development, financed from the European Social Fund and by the Romanian Government under the contract number POSDRU/89/1.5/S/64153.

References

- Ray WZ, Mackinnon SE. Management of nerve gaps: autografts, allografts, nerve transfers, and end-to-side neurotomy. *Exp Neurol*. 2010 May;223(1):77-85. Epub 2009 Apr 5.
- Boyd KU, Nimigan AS, Mackinnon SE. Nerve reconstruction in the hand and upper extremity. *Clin Plast Surg*. 2011;38(4):643-60.
- Moore AM, Ray WZ, Chenard KE, Tung T, Mackinnon SE. Nerve allotransplantation as it pertains to composite tissue transplantation. *Hand (N Y)*. 2009;4(3):239-44. Epub 2009 Mar 21.
- Stefănescu O, Jecan R, Bădoiu S, Enescu DM, Lascăr I. Peripheral nerve allograft, a reconstructive solution: outcomes and benefits. *Chirurgia (Bucur)*. 2012;107(4):438-41.
- Moore AM, MacEwan M, Santosa KB, Chenard KE, Ray WZ, Hunter DA, et al. Acellular nerve allografts in peripheral nerve regeneration: a comparative study. *Muscle Nerve*. 2011;44(2):221-34. Epub 2011 Jun 9.
- Siemionow M, Sonmez E. Nerve allograft transplantation: a review. *J Reconstr Microsurg*. 2007;23(8):511-20.
- Meek MF, Varejão AS, Geuna S. Use of skeletal muscle tissue in peripheral nerve repair: review of the literature. *Tissue Eng*. 2004;10(7-8):1027-36.
- Roganovic Z, Ilic S, Savic M. Radial nerve repair using an autologous denatured muscle graft: comparison with outcomes of nerve graft repair. *Acta Neurochir (Wien)*. 2007;149(10):1033-8; discussion 1038-9. Epub 2007 Aug 23.
- Deal DN, Griffin JW, Hogan MV. Nerve conduits for nerve repair or reconstruction. *J Am Acad Orthop Surg*. 2012;20(2):63-8.
- Gravvanis AI, Lavdas AA, Papalois A, Tsoutsos DA, Matsas R. The beneficial effect of genetically engineered Schwann cells with enhanced motility in peripheral nerve regeneration: review. *Acta Neurochir Suppl*. 2007;100:51-6.
- Hood B, Levene HB, Levi AD. Transplantation of autologous Schwann cells for the repair of segmental peripheral nerve defects. *Neurosurg Focus*. 2009;26(2):E4.
- Kim SM, Lee SK, Lee JH. Peripheral nerve regeneration using a three dimensionally cultured schwann cell conduit. *J Craniofac Surg*. 2007;18(3):475-88.
- di Summa PG, Kingham PJ, Raffoul W, Wiberg M, Terenghi G, Kalbermatten DF. Adipose-derived stem cells enhance peripheral nerve regeneration. *J Plast Reconstr Aesthet Surg*. 2010;63(9):1544-52. Epub 2009 Oct 13.
- Mohammadi R, Azizi S, Delirez N, Hobbenaghi R, Amini K, Malekhetabi P. The use of undifferentiated bone marrow stromal cells for sciatic nerve regeneration in rats. *Int J Oral Maxillofac Surg*. 2012 May;41(5):650-6. Epub 2011 Dec 7.
- Brandt J, Dahlin LB, Lundborg G. Autologous tendons used as grafts for bridging peripheral nerve defects. *J Hand Surg Br*. 1999;24(3):284-90.
- Brandt J, Dahlin LB, Kanje M, Lundborg G. Spatiotemporal progress of nerve regeneration in a tendon autograft used for bridging a peripheral nerve defect. *Exp Neurol*. 1999;160(2):386-93.
- Geuna S, Tos P, Battiston B, Guglielmone R, Giacobini-Robecchi MG. Morphological analysis of peripheral nerve regenerated by means of vein grafts filled with fresh skeletal muscle. *Anat Embryol (Berl)*. 2000;201(6):475-82.
- Santo Neto H, Teodori RM, Somazz MC, Marques MJ. Axonal regeneration through muscle autografts submitted to local anaesthetic pretreatment. *Br J Plast Surg*. 1998;51(7):555-60.
- Lawson GM1, Glasby MA. A comparison of immediate and delayed nerve repair using autologous freeze-thawed muscle grafts in a large animal model. The simple injury. *J Hand Surg Br*. 1995;20(5):663-700.
- Houstava L, Dubový P, Haninec P, Grim M. An alternative preparation of the acellular muscle graft for reconstruction of the injured nerve-morphological and morphometric analysis. *Ann Anat*. 1999;181(3):275-81.
- Risitano G, Cavallaro G, Merrino T, Coppolino S, Ruggeri F. Clinical results and thoughts on sensory nerve repair by autologous vein graft in emergency hand reconstruction. *Chir Main*. 2002;21(3):194-7.
- Alligand-Perrin P, Rabarin F, Jeudy J, Césari B, Saint-Cast Y, Fouque PA, et al. Vein conduit associated with microsurgical suture for complete collateral digital nerve severance. *Orthop Traumatol Surg Res*. 2011;97(4 Suppl):S16-20. Epub 2011 Apr 30.
- Lee YH, Shieh SJ. Secondary nerve reconstruction using vein conduit grafts for neglected digital nerve injuries. *Microsurgery*. 2008;28(6):436-40.
- Kehoe S, Zhang XF, Boyd D. FDA approved guidance conduits and wraps for peripheral nerve injury: a review of materials and efficacy. *Injury*. 2012;43(5):553-72. Epub 2011 Jan 26.
- Deumens R, Bozkurt A, Brook GA. US Food and Drug Administration/Conformit Europe-approved absorbable nerve conduits for clinical repair of peripheral and cranial nerves. Commentary. *Ann Plast Surg*. 2010;65(3):371.

26. Deal DN, Griffin JW, Hogan MV. Nerve conduits for nerve repair or reconstruction. *J Am Acad Orthop Surg.* 2012;20(2):63-8.
27. Shin RH, Friedrich PF, Crum BA, Bishop AT, Shin AY. Treatment of a segmental nerve defect in the rat with use of bioabsorbable synthetic nerve conduits: a comparison of commercially available conduits. *J Bone Joint Surg Am.* 2009; 91(9):2194-204.
28. Mackinnon SE, Doolabh VB, Novak CB, Trulock EP. Clinical outcome following nerve allograft transplantation. *Plast Reconstr Surg.* 2001;107(6):1419-29.
29. Evans PJ, MacKinnon SE, Midha R, Wade JA, Hunter DA, Nakao Y, et al. Regeneration across cold preserved peripheral nerve allografts. *Microsurgery.* 1999;19(3):115-27.
30. Ray WZ, Kale SS, Kasukurthi R, Papp EM, Johnson PJ, Santosa KB, et al. Effect of cold nerve allograft preservation on antigen presentation and rejection. *J Neurosurg.* 2011; 114(1):256-62. Epub 2010 Jun 18.
31. Rovak JM, Bishop DK, Boxer LK, Wood SC, Mungara AK, Cederna PS. Peripheral nerve transplantation: the role of chemical acellularization in eliminating allograft antigenicity. *J Reconstr Microsurg.* 2005;21(3):207-13.
32. Mungara AK, Brown DL, Bishop DK, Wood SY, Cederna PS. Anti-CD40L monoclonal antibody treatment induces long-term, tissue-specific, immunologic hyporesponsiveness to peripheral nerve allografts. *J Reconstr Microsurg.* 2008;24(3):189-95. Epub 2008 Apr 5.
33. Brenner MJ, Mackinnon SE, Rickman SR, Jaramillo A, Tung TH, Hunter DA, et al. FK506 and anti-CD40 ligand in peripheral nerve allotransplantation. *Restor Neurol Neurosci.* 2005;23(3-4):237-49.
34. Nagao RJ, Lundy S, Khaing ZZ, Schmidt CE. Functional characterization of optimized acellular peripheral nerve graft in a rat sciatic nerve injury model. *Neurol Res.* 2011;33(6):600-8.
35. Hanno Millesi. Microsurgical repair of peripheral nerves. In: Smith JW, Grabb WC, Aston SJ editors. *Grabb and Smith's Plastic Surgery*, 4th ed. Little Brown; 1991. p. 1053-1075.
36. Tung TH. Tacrolimus(FK 506): Safety and applications in reconstructive surgery. *Hand (N Y).* 2010 Mar;5(1):1-8. Epub 2009 Apr 11.
37. Lanzetta M, Dubernard JM, Petruzzo Palmina. *Hand transplantation.* Springer-Verlag (Italia); 2007.
38. Baumeister S, Kleist C, Döhler B, Bickert B, Germann G, Opelz G. Risks of allogeneic hand transplantation. *Microsurgery.* 2004;24(2):98-103.
39. Moore AM, MacEwan M, Santosa KB, Chenard KE, Ray WZ, Hunter DA, et al. Acellular nerve allografts in peripheral nerve regeneration: a comparative study. *Muscle Nerve.* 2011;44(2):221-34. Epub 2011 Jun 9.
40. Moore AM, Ray WZ, Chenard KE, Tung T, Mackinnon SE. Nerve allotransplantation as it pertains to composite tissue transplantation. *Hand (N Y).* 2009;4(3):239-44. Epub 2009 Mar 21.
41. Tung TH. Tacrolimus (FK506): Safety and Applications in Reconstructive Surgery. *Hand (N Y).* 2010;5(1):1-8. Epub 2009 Apr 11.
42. Pollard JD, Fitzpatrick L. A comparison of the effects of irradiation and immunosuppressive agents on regeneration through peripheral nerve allografts: an ultrastructural study. *Acta Neuropathol.* 1973;23(2):166-80.
43. Easterling KJ, Trumble TE. The treatment of peripheral nerve injuries using irradiated allografts and temporary host immunosuppression (in a rat model). *J Reconstr Microsurg.* 1990;6(4):301-7; discussion 309-10.
44. Szykaruk M, Kemp SW, Wood MD, Gordon T, Borschel GH. Experimental and clinical evidence for use of decellularized nerve allografts in peripheral nerve gap reconstruction. *Tissue Eng Part B Rev.* 2013;19(1):83-96. Epub 2012 Oct 3.
45. Mackinnon SE, Hudson AR, Falk RE, Kline D, Hunter D. Peripheral nerve allograft: an immunological assessment of pretreatment methods. *Neurosurgery.* 1984;14(2):167-71.
46. Evans PJ, Mackinnon SE, Levi AD, Wade JA, Hunter DA, Nakao Y, et al. Cold preserved nerve allografts: changes in basement membrane, viability, immunogenicity, and regeneration. *Muscle Nerve.* 1998;21(11):1507-22.
47. Fansa H, Lassner F, Kook PH, Keilhoff G, Schneider W. Cryopreservation of peripheral nerve grafts. *Muscle Nerve.* 2000;23(8):1227-33.
48. Avance nerve graft - instructions for use, available online at www.axogeninc.com.
49. Kvist M, Sondell M, Kanje M, Dahlin LB. Regeneration in, and properties of, extracted peripheral nerve allografts and xenografts. *J Plast Surg Hand Surg.* 2011;45(3):122-8.
50. Hu J, Zhu QT, Liu XL, Xu YB, Zhu JK. Repair of extended peripheral nerve lesions in rhesus monkeys using acellular allogenic nerve grafts implanted with autologous mesenchymal stem cells. *Exp Neurol.* 2007;204(2):658-66. Epub 2007 Jan 10.
51. Jia H, Wang Y, Tong XJ, Liu GB, Li Q, Zhang LX, Sun XH. Sciatic nerve repair by acellular nerve xenografts implanted with BMSCs in rats xenograft combined with BMSCs. *Synapse.* 2012;66(3):256-69. Epub 2011 Dec 13.
52. Mohammadi R, Azizi S, Delirez N, Hobbenaghi R, Amini K. Comparison of beneficial effects of undifferentiated cultured bone marrow stromal cells and omental adipose-derived nucleated cell fractions on sciatic nerve regeneration. *Muscle Nerve.* 2011 Feb;43(2):157-63. Epub 2010 Nov 16.
53. Mohammadi R, Azizi S, Amini K. Effects of undifferentiated cultured omental adipose-derived stem cells on peripheral nerve regeneration. *J Surg Res.* 2013;180(2):e91-7. Epub 2012 Apr 27.