

Effects of the radiofrequency interference with modified titanium surgical clips on liver parenchyma – an in vivo experiment

D. Gonganau-Nitu¹, R.R. Scurtu¹, C.G. Precup¹, G. Dindelegan¹, A. Biro¹, C. Crisan¹, S. Cocu¹, C. Popa², C. Ciuce¹

¹Department of Surgery No 1, University of Medicine and Pharmacy Iuliu Hatieganu Cluj-Napoca, Romania

²Technical University, Cluj-Napoca, Romania

Rezumat

Efectele interferenței radiofrecvenței cu agrafele de titan modificate la nivelul parenchimului hepatic – experiment in vivo

Scop: Cercetarea testează biocompatibilitatea mai multor tipuri de agrafe de titan la nivelul ficatului în prezența radiofrecvenței, în funcție de distanța plasării agrafei și timp. **Material și metodă:** Este un studiu experimental pe porc care urmărește modificările histologice (inflamație, necroză, fibroză) ce apar la interfața dintre agrafele de Ti (modificate prin tratare termică în vid la temperaturi înalte - 1000°C și 1150°C) și ficat, în condițiile prezenței radiofrecvenței. Agrafele au fost plasate la nivelul ficatului de porc la distanța de 0.5 cm, 1,5 cm și 2,5 cm față de sonda de RF. Inflamația, necroza și fibroza au fost măsurate la 7, 14 și 28 de zile.

Rezultate: Alterarea tisulară scade odată cu creșterea distanței la care au fost implantate agrafele. Necroza și inflamația induse de radiofrecvență în țesuturile din jurul agrafelor de titan implantate se diminuează în timp, dar fibroza nu devine mai pronunțată. Agrafele de titan modificate la 1000°C duc la o necroză mai puțin pronunțată decât agrafele de titan nemodificate. Efectele nu se mențin însă pentru inflamație sau fibroză. Tipul de agrafă moderează efectul distanței asupra fibrozei și necrozei. Tipul de agrafă moderează relația timp-inflamație.

Concluzii: Datele obținute sugerează că nu există un singur tip de agrafe de titan care prezintă o biocompatibilitate net superioară celorlalte în toate situațiile. Biocompatibilitatea agrafelor de titan depinde de distanța la care sunt acestea amplasate: cele netratate mai aproape (sub 1cm față de sonda de RF), cele tratate termic mai departe (> 1cm).

Cuvinte cheie: Agrafe de titan, radiofrecvența, inflamație, necroză, fibroză

Abstract

Aim: This study sets out to test the biocompatibility of titanium clips in liver, in the presence of radiofrequency. Biocompatibility is assessed at various distances from the RF electrode and different points in time.

Method: It is an experimental study conducted on pigs and makes use of histological changes that occur at the liver - titanium interface in presence of RF to test hypotheses. The titanium clips were modified in high vacuum (10⁻⁵ atm) by heating them at 1000 °C și 1150 °C. Titanium clips were placed in liver at 0.5, 1.5 and 2.5 cm from RF probe. At 7, 14 and 28 days the inflammation, necrosis and fibrosis were assessed.

Results: The histological alterations decrease with the distance of implantation of titanium clips. The inflammation and necrosis nearby the titanium clips decrease in time, but the fibrosis does not increase, as expected. The modified titanium at 1000°C clips cause less necrosis than commercial titanium clips. The moderator role of clip type between distance and cell alteration is empirically supported only for fibrosis and necrosis. The moderator role between time and cell alteration is supported only for inflammation.

Conclusions: Experimental data suggests there are no preferred

Corresponding author:

Prof. Ciuce Constantin MD, PhD
University of Medicine and Pharmacy
Iuliu Hatieganu Cluj-Napoca, Romania,
Department of Surgery, Clinicilor Street,
No 3-5, 400006 Cluj-Napoca, Romania
E-mail: cciuce@umfcluj.com

surgical clips in all situations. The biocompatibility of the titanium clips depends on the distance from the RF probe. The commercial ones prove less damaging if they are placed close to the RF probe (less than 1 cm) and those that were treated at 1150 C have a better bio-compatibility if placed more than 1 cm from RF probe.

Key words: Thermal modified titanium clips, radiofrequency, inflammation, necrosis, fibrosis

Introduction

Liver trauma counts for 15-20 % of abdominal trauma and accounts about 50% of the mortality following abdominal injuries. Liver surgery is considered an intervention with high hemorrhagic risk (1).

One of the procedures used for stopping the consecutive haemorrhage of liver after surgical intervention is radiofrequency (RF). RF can be used by itself or in combination with other surgical procedures, in order to limit blood loss (ex. definitive haemostasis with suture) (2). One of the limitations of these methods is that biliary and blood vessels larger than 0.3-0.6 cm in diameter cannot be obturated efficiently by RF (3,4). Furthermore, titanium clips are often used for an efficient haemostasis. Titanium is a biological inactive metal, without magnetic properties, which makes it compatible with procedures that make use of magnetic fields (ex MRI).

There are numerous studies on titanium biocompatibility, but most of them analyze the relationship between metal and bone tissue. Oxidative metabolism is perturbed by the presence of titanium in cells and has implications in cell apoptosis and cell necrosis. In organs with phagocytosis (ex. liver, spleen lung), titanium can be found in macrophages (5), where it induces an increase of oxygen radicals (6). Those radicals are involved in tissue necrosis and they damage the contact surface of the implant. The mentioned studies assert that only large doses of titanium induce a chronic inflammation of the epithelium. Nevertheless, those studies make use of oxide titanium powder, thus omitting an important aspect of biocompatibility – the presence of the implant itself in the organism. Studies on the liver reaction at titanium implants in conditions of RF are rare in literature (7).

This study addresses the limitations of previous research by setting out to test the biocompatibility of titanium clips in liver in with the presence of radiofrequency. Biocompatibility will be assessed at various distances from the RF electrode and different points in time. This experimental study is conducted on pigs and makes use of histological changes that occur at the liver – titanium interface to test hypotheses.

We begin with a brief overview of the extant literature, presenting the in vitro and in vivo studies that explore the effects of radiofrequency after surgery on liver tissue in the presence of titanium clips. Next, we introduce several aspects of titanium biocompatibility and the devices made from it. Then we present some considerations about changes in internal

structure when the titanium devices are subject of thermal treatment and the injuries induced in the host organism. Following these two perspectives, we lay out our experimental design, present the method and results. At the end, we organize and interpret our results around the underlying question of this research: what is the type of titanium clips, and what the conditions of implantation, that lead to a minimal alteration of tissue? In other words, what are the conditions that maximize the biocompatibility of titanium?

Radiofrequency in liver surgery

Heavy blood loss in surgical interventions of the liver is a fact. The need to control in a quick manner the haemorrhage imposed the development of new devices or changing the initial purpose of existent ones. The stapler, a device used for the suture of the skin, was chosen in the beginning. The major drawback was the nature of the metallic clips: they were made from stainless steel for medical use. Consequently, devices that use titanium clips or titanium alloys were developed.

Radiofrequency is customarily used to treat malignant tumours of the liver (8). When certain conditions are met (numbers of malignant metastases are less than 3 and not exceed 3 cm in diameter) radiofrequency is the preferred method (9,10). Titanium clips used in previous surgical procedures are prone to interfere with the electromagnetic field generated by RF.

One of the most cited study is an in vitro experiment on pig liver tissue. In this study, the authors try to asses the safety of applying RF in the presence of titanium clips. The implants were placed in ex vivo pig liver at different distances from the RF needle and RF was applied for 3 minutes. The lesion induced by RF included the first clip, placed at 1 cm from the RF needle. They studied the tissue surrounding the other clips and concluded that no coagulation lesions occurred around them. There were some notable differences between tissues that surround the clips and other equivalent regions of coagulation, but because the lesion was included in the final RF coagulation lesion, is the authors concluded it was safe to use the RF on human subjects (11).

Following this study, there is a case report of a patient with malignant pathology of the liver that underwent previous surgical treatment and presented metallic implants in the resection edge. The patient suffered a recurrence of initial pathology and was treated with RF percutaneous. After the intervention, investigations revealed coagulation lesions developed after an electric arch between the RF probe and the titanium clips, despite the fact that the probe was placed at 7 cm from the closest clip (12).

In vivo investigations show that in general the lesions induced by RF are smaller than in vitro lesions. Also, the form of the lesion depends on the presence of blood vessels larger than 3mm (4) – 7 mm (13) in the vicinity of the RF probe, which act as a heat sink (4). Owing to those facts, the first hypothesis of the study asserts that:

H1. The closer the titanium clips are to the RF probe, the more pronounced the tissue alteration will be.

The hepatic tissue reacts to injuries by changes in its functions and in its structure. Investigating the alterations in functions can sometimes be a difficult thing to do, due to the numerous functions that liver has (more than 500).

Changes in the histological structure of the liver are easier to investigate due to their smaller number: necrosis, inflammation and restoration (ad integrum and/or fibrosis) (14).

Based on these tissue changes, histologic scores were developed. The most utilised score to assess histological changes in hepatic tissue is the Knodell score, which is based on fibrosis, necrosis and inflammation (15).

After the implantation of titanium clips in the liver, followed by RF, a gradient of tissue changes will appear. Consequently, our hypothesis states that:

- H2a. The fibrosis of hepatic tissue induced by RF becomes more noticeable in time.
- H2b. The necrosis of hepatic tissue induced by RF will diminish in time.
- H2c. The inflammation of hepatic tissue induced by RF will diminish in time.

Titanium biocompatibility

After RF, the probe is retracted, but the titanium clips remain in organism most of the cases for a long period of time. It is important to recognise the modifications that titanium suffers after RF and the reaction of the tissue to these clips.

Biocompatibility is defined as: (1) the capacity of a material to function correctly in conditions imposed by the host internal medium; (2) the quality of material to have a non-toxic effect on the host; (3) the tissue response to implanted material compared with tissue response to a control material determined before (7). Some authors consider this definition to be incomplete, because it refers to the material only, and neglects aspects concerning the device itself (16). In the next section, we overview the physical and chemical modifications that can change the biocompatibility of the titanium as a material, as well as the devices derived from it.

Titanium has an excellent corrosion resistance. This unique property made it the material of choice in medicine. Its ability to develop a very thin layer of titanium oxide even at simple exposure to atmospheric oxygen is responsible for its corrosion resistance. This layer follows the rules of passivation regarding stability, permeability and adherence to substrate. Internal fluids have multiple ionic species in solution and a gradient of partial pressure of oxygen that favour electrochemical corrosion. Furthermore, inflammatory processes or infections induce a dropping of pH in that region and lower even more the partial pressure of oxygen. The oxygenated water produced by inflammatory cells in the proximity of the implant induces a pH below 5 for a few days. All these processes delay the passivation of titanium when the protective coating of the implant is altered during manipulation.

The internal region of surgical clips constitutes a place for localised corrosion. Because of the nature of the clips' bending (always one arm over the other), small cracks in the oxide layer appear in this region. The cause is the length of the bending

radius. The radius is smaller than the thickness of the material and breaks the rule of deformation without cracking.

Ductility is the property that influences the behaviour of titanium clips when a bending force is applied. This property is determined by the internal crystalline structure. Pure titanium and its alloy present two forms of crystallisation (alpha and beta). The beta structure is responsible for its strength and hardness at room temperature. Malleability and ductility are negatively influenced by this type of crystallisation compared with the alpha structure. Changes in the internal structure of titanium are possible by heating it at temperatures exceeding 885°C, when crystallisation form changes from beta to alpha, and over 1000°C, when the size of the crystal grain is growing.

Changes in the internal structure determine a paradox from a biocompatibility point of view. Thick structures resulted after high temperature treatment of titanium are more ductile and have less internal stress, but are more prone to raise their temperature when electromagnetic fields are present, by rising their electric charge (11). Releasing the stress accumulated in the internal structure can lower the risk of cracking when bending.

As a result of these facts we can say that we have significant histologic changes in liver tissue near the clips modified at high temperature compared with the other two types of clips. The third hypothesis of the study states:

- H3a. Titanium clips modified at 1000°C will induce less pronounced histologic changes than commercial titanium clips.
- H3b. Commercial titanium clips will induce less pronounced histologic changes than titanium clips modified at 1150°C

The distance between the RF probe and clips will also influence the histological changes. Furthermore, we expect different types of clips to have different effects in time. According to these assumptions, the last hypotheses of the study are:

- H4. The type of titanium clip has a moderator role in the relation between the distance of titanium clips from the RF probe and tissue alterations.
- H5. The type of titanium clip has a moderator role in the relation between time and tissue alteration, with different tissue changes occurring for different types of clips at various points in time.

Study design

To test our hypotheses, an experimental 3x3x3 design was developed.

The first independent variable, the distance of titanium clips from the RF probe, has three modalities: 0.5, 1.5, 2.5 cm.

For the second independent variable, the titanium clips, we proposed three modalities: commercial titanium clips, 1000°C and 1150°C modified titanium clips.

To establish the changes produced in the tissue at different points in time, we chose to measure those effects at 7, 14 and 28 days.

To measure the changes in the liver tissue, we used a modified Knodell score. Fibrosis, inflammation and necrosis

were assessed on a scale from 1 to 4. The presence of giant cells or granulomas was also noted. For fibrosis, we added a new parameter at the regular modifications that define the Knodell score: the thickness of perilobular fibrosis measured in cell layers when neither of the parameters defining the Knodell score were observed, we measured the modification of fibrosis with our new parameter.

Subjects and materials

We used six Great White pigs with a mean weight of 25 kilograms with ad libitum access at standard laboratory alimantation.

The tested biomaterials were titanium clips (SLS-Clip V3120.1 medium-large, Vitalitec International, France). The titanium clips were thermally treated in high vacuum, at 10⁻⁵ atm. When high vacuum was achieved, the temperature was raised at 1000°C (Ti1) and 1150°C (Ti2) and applied for 60 minutes. Titanium clips were left to cool down gradually until the next day.

Radiofrequency was applied with a RF probe (Starburst™ SDE, AngioDynamics, USA) coupled at a RF generator (RITA® Model 1500X RF, AngioDynamics, USA).

Method

Anaesthesia

In the day of the experiment, lab animals were restricted on food and water. Premedication consisted of intramuscularly administered Ketamin 10% and Xylazine 2% (2:1). After induction, antibiotic prophylaxis was conducted with 0.5g Zinacef® (Cefuroxime® 750mg, GlaxoSmithKline, Italy). General anaesthesia was performed with oro-tracheal intubation on Halothane (Narcotan® 150g, Leciva a.s. Cehia) pivot in 1-2 % volumes. For muscular relaxation, we used Midazolam (0.5 mg/kg i.m.), Fentanyl (0.5mg/h i.v.) and Pancuronium (0.25 mg/kg/h i.v.). During the surgical intervention, we administered Ringer lactate solution i.v. and 750 mg of Zinacef®.

Cardiac and ventilatory monitoring was performed with an ECG monitor and pulseoxymetre (Ohmeda Biox 3700e, Ohmeda Biox®, BOC Healthcare Inc, USA).

Analgesia after surgical intervention was realised with 3mg/kg i.m. Ketoprofen (Profenid® 100mg, Rhone-Poulenc Rorer, France) twice a day during the first two days.

During the first 24 hours after the intervention, only liquids and semisolid alimantation was allowed. Standard lab alimantation was provided afterwards.

Surgery

Following anaesthesia, the animal's skin was shaved and swabbed with Betadine 10% (Povidone Iodine 10%, Egis Pharmaceutical LTD- Hungary).

Xiphoid-umbilical laparotomy was performed and the largest hepatic lobe that could be mobilized without traction via incision was isolated. The placement of the radiofrequency probe was marked along with the place of titanium clips

located at 0.5 cm, 1.5 cm and 2.5 cm from the probe following the same direction cranially and caudally. Hepatic trauma was induced perpendicular to this direction, on the left and right side, at the same distance from the radiofrequency probe. The titanium Ti1 clips were placed caudally and the Ti2 clips were placed cranially. The same type of clips was used for the injured areas, Ti1 being placed to the right of the RF probe and Ti2 to the left.

The unmodified Ti3 clips were placed at the same distance from the RF probe, along the bisect line of the right angles formed by the directions of the Ti clips.

After the clips were placed, the probe was inserted in parenchyma and connected to the RF generator for four minutes, at wattage of 90kW and a probe tip temperature of 105°C.

At the end of the surgery, after haemostasis control, a continuous suture of the abdomen was performed using absorbable running sutures (Polisorb® 2, Autosuture, Tyco USA).

Histological processing

The histological material was taken at 7, 14, and 28 days, euthanizing the animal. The histological material was paraffin-embedded, sliced in 5µm samples, hematoxylin-eosin stained and microscopically analyzed in order to appreciate tissue alterations (necrosis, inflammation and fibrosis).

The fibrosis, inflammation and necrosis were qualitatively assessed by two investigators, who marked the parameters from 1 to 4, on five random microscopic fields, at a magnification of 400x of the histological sample.

Data analysis

The collected data was statistically analysed using specialized software (SPSS v17.0). The hypotheses were tested using covariance analysis (ANOVA).

Results

The first hypothesis received empirical support for two of the three indicators of cellular alteration. Tissue alteration decreases as the distance between the inserted clips increases. For inflammation, $F(2,142)=2.01$, $p=.138$; for fibrosis, $F(2,142)=29.91$, $p=.000$; and for necrosis $F(2,142)=4.23$, $p=.16$. Each of the three markers of cellular alteration (i.e., inflammation, fibrosis and necrosis) has an obvious negative trend. Despite being statistically not significant, inflammation also respects the hypothesized trend.

The second hypothesis (referring to time) received partial empirical support as well. Radiofrequency-induced necrosis and inflammation in the tissues surrounding the implanted titanium clips diminish over time (H2b and c), but the fibrosis does not become more pronounced (H2a). For inflammation, $F(2,142)=16.25$, $p=.000$; for fibrosis, $F(2,142)=7.08$, $p=.001$; and for necrosis $F(2,142)=6.68$, $p=.002$. A detailed analysis of tissue evolution over time revealed a non-linear pattern: all three markers presented an important inflexion point at day 14.

According to hypothesis 3, the titanium clips heated

Table 1. *t* Test for independent samples for modified titanium clips and commercial titanium clips

| Descriptive statistics | | | | | t Test: Ti1 (1000°C) vs. Ti3 (commercial) | | | t Test: Ti2 (1150°C) vs. Ti3 (commercial) | | |
|------------------------|------------|-----|------|-------|-------------------------------------------|----|-----------------|-------------------------------------------|----|-----------------|
| | | N | Mean | SD | t | df | Sig. (2-tailed) | t | df | Sig. (2-tailed) |
| Inflammation | 1000 °C | 65 | 1.83 | .876 | .127 | 83 | .899 | -.904 | 78 | .369 |
| | 1150 °C | 60 | 1.57 | .945 | | | | | | |
| | Commercial | 20 | 1.80 | 1.152 | | | | | | |
| | Total | 145 | 1.72 | .948 | | | | | | |
| Fibrosis | 1000 °C | 65 | 2.45 | .985 | -.015 | 83 | .988 | -.498 | 78 | .620 |
| | 1150 °C | 60 | 2.32 | 1.033 | | | | | | |
| | Commercial | 20 | 2.45 | 1.050 | | | | | | |
| | Total | 145 | 2.39 | 1.009 | | | | | | |
| Necrosis | 1000 °C | 64 | 1.73 | .895 | -3.397 | 82 | .001 | -2.723 | 78 | .008 |
| | 1150 °C | 60 | 1.85 | .954 | | | | | | |
| | Commercial | 20 | 2.50 | .827 | | | | | | |
| | Total | 144 | 1.89 | .940 | | | | | | |

(modified) at 1000°C cause less tissue alteration than the unheated clips (i.e., unmodified) (H3a), and the latter less than the clips heated (modified) at 1150°C. As shown in *Table 1*, the first part of the hypothesis was empirically supported for necrosis. The second part of hypothesis was not confirmed, the titanium clips heated at 1150°C cause significant less tissue alteration than the unheated clips, but the direction of the relationship is opposite to our expectations. Neither inflammation nor fibrosis developed according to expectations.

The fourth hypothesis (which asserts the moderator role of clip type between distance and cell alteration) is empirically supported for fibrosis and necrosis (see *Table 2*). For both variables, the direct effect of distance and clip type, as well as the interaction effect, are statistically significant. Although not statistically significant, an interaction effect is also present in the case of inflammation (see *Fig. 1*). As shown in the three charts in *Fig. 1*, for both fibrosis and necrosis, the titanium processed at 1000°C has an extremely different pattern compared to the titanium processed at 1150°C. Furthermore, the slopes of their effects are in opposite direction from unmodified titanium clips.

The fifth hypothesis (referring to the moderator role of clip type in the relation between time and cellular alteration) also received partial empirical support. In this case, the inflammation was the dependent variable whose interaction effect between clip type and day was significant (see *Table 3*). Neither fibrosis nor necrosis showed statistically significant effects, but the patterns of the three clip types are also different, as seen in *Fig. 2*.

Table 2. *Regression results for interaction effect between clip type and distance on inflammation, necrosis and fibrosis*

| Step | Inflammation | Fibrosis | Necrosis |
|-----------------------|--------------|----------|----------|
| 1 Distance | -.40** | -.79*** | -.60*** |
| Clip type | -.37 | -.49** | -.30 |
| 2 Distance *Clip type | .41 | .56** | .68*** |
| Δ F | 2.04 | 4.95** | 6.32*** |
| R ² | .04 | .25 | .15 |
| AdjR ² | .02 | .23 | .13 |

Discussions

The aim of this study was to determine the conditions that improve titanium biocompatibility. In order to achieve this, we relied on the description of histological phenomena occurring in the hepatic parenchyma in the presence of RF and titanium clips, in various experimental conditions (different types of titanium clips, distance and time). In the following section we summarise the influence of each variable individually (distance, time, clip type), and then assess how these variables, taken together, may lead to lesser tissue damage.

Distance

The negative slopes of inflammation, fibrosis and necrosis in relation to distance from *Fig. 1* is similar to what extant literature reports (17). This is an important consideration in assessing the changes we have made to the Knodell Score in this study: it confirms this modification does not alter the results or their interpretation. As proved in previous studies (11, 12), the electric current used in RF induces an uneven heating of the tissue, with a pick near the RF probe and decreasing with distance. As the temperature decreases, the hepatic tissue is less damaged and the phenomena of fibrosis, inflammation and necrosis occur with diminished intensity. However, our study demonstrates that this reaction only occurs for modified titanium clips. Data collected in this study support the assertion that changes made to the titanium clips increased their biocompatibility (i.e., they led to the expected modification in tissue response).

Table 3. *Regression results for interaction effect between clip type and time on inflammation, necrosis and fibrosis*

| Step | Inflammation | Fibrosis | Necrosis |
|-------------------|--------------|----------|----------|
| 1 Day | .25 | -.02 | .28 |
| Clip type | .19 | -.11 | -.07 |
| 2 Day *Clip type | -.46** | -.02 | -.08 |
| Δ F | 3.85** | .01 | .13 |
| R ² | .05 | .01 | .08 |
| AdjR ² | .03 | -.00 | .06 |

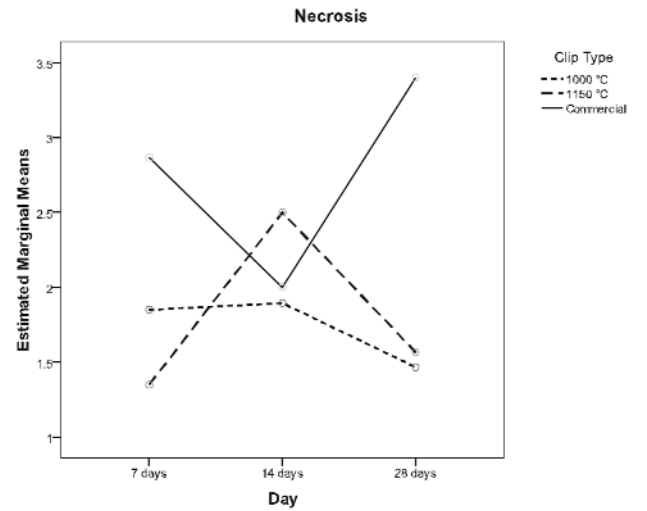
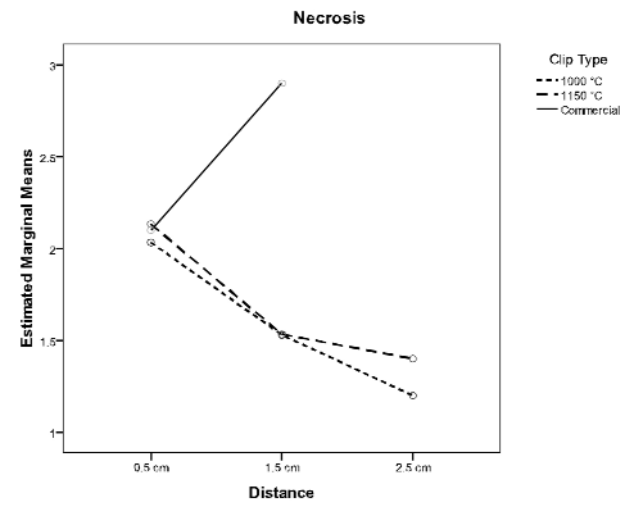
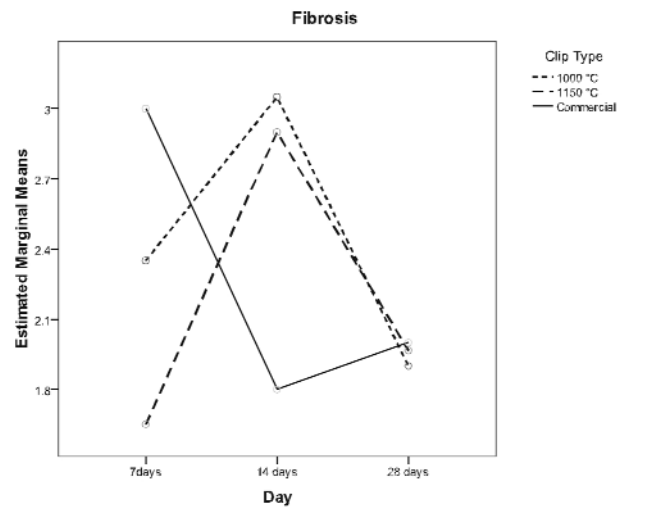
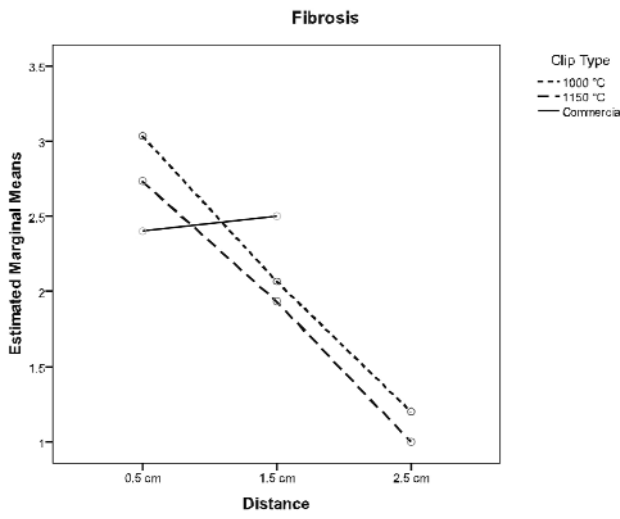
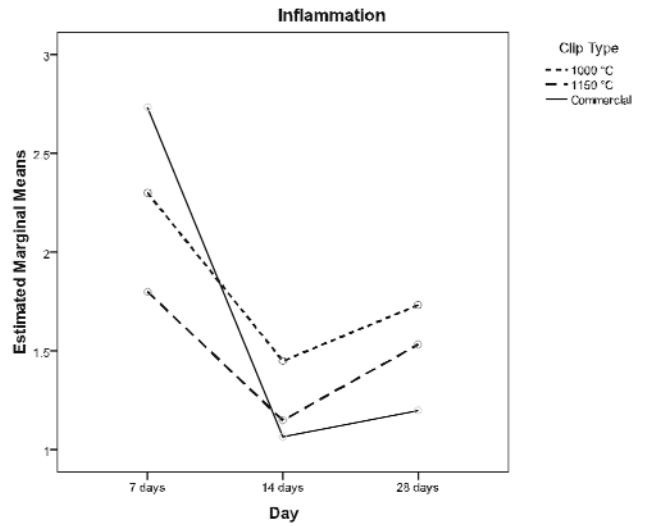
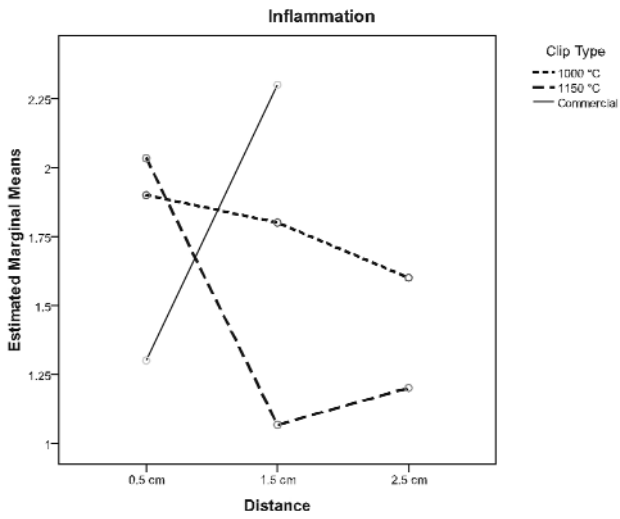


Figure 1. Interaction effect between clip type and distance on inflammation, necrosis and fibrosis

Figure 2. Interaction effect between clip type and time on inflammation, necrosis and fibrosis

These results can be explained by the fact that the internal structure of the clips has a direct impact on the distribution of thermal energy in tissues. Therefore, our modifications of the clips contributed positively in inducing a lower current intensity in the clip, hence producing less pronounced tissue alterations.

Time

If inflammatory processes have a maximum in the early days, the peaks of fibrosis and necrosis are consequent to inflammation. As fibrosis increases in intensity, secondary necrosis phenomena occur, followed by inflammation augmentation. A detailed analysis of the trend of the three clip types emphasise that the curves' inflexions for fibrosis and necrosis on day 14 are especially due to modified clip curves. Fibrosis is the parameter with the strongest inflexion at this point in time, suggesting an acceleration of repairing processes that occur in hepatic parenchyma in the presence of modified clips as compared to unmodified ones. However, at the end of the studied period, the intensities of the phenomena are nearly similar. An exception is the necrosis phenomena, which presents an upward slope for the unmodified clips.

Type of clip

The analysis of the tissue alterations depending on clip type variable points out that there are differences in the presence of modified clips at 1000°C and 1150°C. For those types of clips, all mean values of the measured parameters were lower than those for normal clips, indicating their apparent superiority. However, as the interaction analyses prove, the apparent superiority of those clips does not hold for all distance and time conditions.

Interaction effects

Analyzing the interaction between distance and clip type, as well as between time and clip type, we can assert that there is no unequivocal response to demonstrate the superiority of a particular type of clip on others. Various types of clips can lead to lesser tissue alteration, under different circumstances. More precisely, the unmodified clip proves to be less damaging when placed near the RF probe, while the modified ones perform better at a greater distance. The clips modified at 1150°C prove to induce the least damage in the specified conditions.

Also, modified and unmodified clips have different fibrosis and necrosis patterns in time. The largest discrepancy is present for necrosis, which, after a relative similarity of all clips on day 14, attains much higher values for unmodified clips after 28 days. In brief, the tissue alterations the clips induce have different patterns in time, with modified clips aggravating the parameters at day 14, and then improving, while unmodified clips being more compatible at day 14, and then decreasing. Our analysis so far points that modified clips may better stand the test of time and prove to be more compatible in the long run. However, biocompatibility tests should be run after longer periods, to test this proposition.

Limitations

One of the major limitations of this study is given by the unequal number of observations in the various experimental conditions. Due to complications during surgery anaesthesia, two animals died shortly after surgery, and a third one died the second day. The analysed samples were collected from three animals.

The area exposed to RF, especially after a longer period of time (14 – 28 days), undergoes extensive morphological transformations, resulting in the inability to properly identify the placement of titanium clips. This, corroborated with experimental death, led to the impossibility of carrying out a full analysis of the distance variable to normal clips at 2.5 cm.

The limitation due to the time variable should be investigated in further studies, along with the effects of RF influence on titanium biocompatibility within a longer period of time, including the 28 days period.

Conclusions

In conclusion, the phenomena induced by RF in the hepatic tissue using modified titanium clips are generally less intense than those developed around the commercial, unmodified titanium clips. The preferred modification for the titanium clips resulting from the data is the clip vacuum baking at a temperature of 1150°C. Furthermore, our results indicate the circumstances under which each type of clip has an increased biocompatibility. Hence, it is preferable to place commercial, unmodified titanium clips at a short distance from the RF probe, while using modified titanium clips at a greater distance (more than 1 cm).

Acknowledgements

This work was supported by CEEEX 145/2006 grant.

References

1. Khan AN, Vadeyar H, Macdonald S, Chandramohan C. Liver. Trauma. eMedicine, 2008.
2. Yao P, Gunasegaram A, Ladd LA, Daniel S, Morris DL. An experimental study of the treatment of liver injury with InLine RFA. HPB (Oxford). 2007;9(1):37-41.
3. Frich L, Mala T, Gladhaug IP. Hepatic radiofrequency ablation using perfusion electrodes in a pig model: effect of the Pringle manoeuvre. Eur J Surg Oncol. 2006;32(5):527-32. Epub 2006 Apr 3.
4. Lu DS, Raman SS, Vodopich DJ, Wang M, Sayre J, Lassman C. Effect of vessel size on creation of hepatic radiofrequency lesions in pigs: assessment of the "heat sink" effect. AJR Am J Roentgenol. 2002;178(1):47-51.
5. Olmedo D, Guglielmotti MB, Cabrini RL. An experimental study of the dissemination of Titanium and Zirconium in the body. J Mater Sci Mater Med. 2002;13(8):793-6.
6. Olmedo DG, Tasat DR, Guglielmotti MB, Cabrini RL. Effect of titanium dioxide on the oxidative metabolism of alveolar macrophages: an experimental study in rats. J Biomed Mater Res A. 2005;73(2):142-9.

7. Oshida Y. *Bioscience and Bioengineering of titanium materials*. Oxford: Elsevier; 2007. p. 440.
8. Popescu I, Ionescu M, Alexandrescu S, Ciurea S, Hrehoreț D, Sârbu-Boeți P, Boroș M, Croitoru A, Anghel R. Surgical treatment of liver metastases from colorectal cancer. *Chirurgia (Bucur)*. 2006;101(1):13-24. [Article in Romanian]
9. Lau WY, Lai EC. The current role of radiofrequency ablation in the management of hepatocellular carcinoma: a systematic review. *Ann Surg*. 2009;249(1):20-5. Comment in: *Ann Surg*. 2009;250(3):497-8; author reply 498.
10. Mulier S, Ni Y, Jamart J, Ruers T, Marchal G, Michel L. Local recurrence after hepatic radiofrequency coagulation: multivariate meta-analysis and review of contributing factors. *Ann Surg*. 2005; 242(2):158-71.
11. Boll DT, Lewin JS, Duerk JL, Merkle EM. Do surgical clips interfere with radiofrequency thermal ablation? *AJR Am J Roentgenol*. 2003;180(6):1557-60.
12. Kerr JM, NiMhuircheartaigh NM, McEntee GP, Fenlon HM. Extension of hepatic necrosis secondary to current arcing to surgical clips: a potential complication of radiofrequency ablation. *Abdom Imaging*. 2009;34(4):491-3.
13. Bangard C, Gossmann A, Kasper HU, Hellmich M, Fischer JH, Hölscher A, et al. Experimental radiofrequency ablation near the portal and the hepatic veins in pigs: differences in efficacy of a monopolar ablation system. *J Surg Res*. 2006; 135(1):113-9. Epub 2006 May 4.
14. Burt AD, Portmann B, Ferrell LD. *MacSween's pathology of the liver*. Philadelphia, PA: Churchill Livingstone/Elsevier; 2007.
15. Desmet VJ, Knodell RG, Ishak KG, Black WC, Chen TS, Craig R, et al. Formulation and application of a numerical scoring system for assessing histological activity in asymptomatic chronic active hepatitis (*Hepatology* 1981;1:431-435). *J Hepatol*. 2003; 38(4):382-6. Comment on: *Hepatology*. 1981;1(5):431-5.
16. Williams D. Revisiting the definition of biocompatibility. *Med Device Technol*. 2003;14(8):10-3.
17. Vinay Kumar, Nelso Fausto, Abbas A. Liver and biliary tract. In: Robbins & Cotran, editors. *Pathologic Basis of Disease*, Seventh Edition. Elsevier/Saunders; 2004. p. 877-938.